ΠΕΡΙΣΤΡΟΦΙΚΗ ΑΘΗΡΕΚΤΟΜΗ

ΓΡΑΪΔΗΣ ΧΡΗΣΤΟΣ

Επεμβατικός Καρδιολόγος, FSCAI
Euromedica-Κυανούς Σταυρός
Θεσσαλονίκη

Can we have the right tool to do the job ?

A thorough knowledge of the basic angioplasty equipment is required for coronary intervention.

✓**The correct choice of equipment can make a complex intervention appear effortless,**

✓***whereas the less appropriate equipment choices can make a straightforward intervention, laborious and challenging*.**

David Auth first described rotational ablation in 1986 **as a technique for winding up coronary thrombus at low rotational speeds, thus capturing it on the rotating burr and shaft.**

So what has happened since the introduction of rotational ablation?



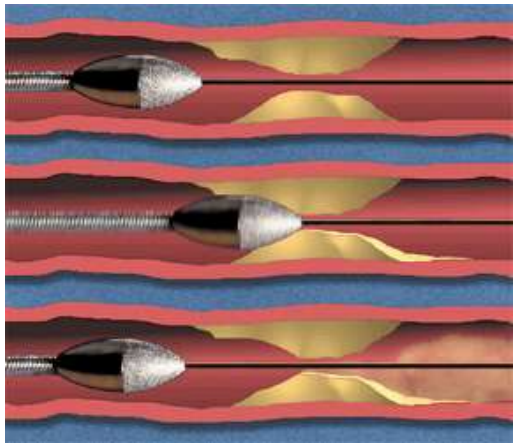

✓ ***We began with great enthusiasm*** **for a technique unlike Gruentzig's balloon, but the initial hope for a lower restenosis rate due to lack of barotrauma and vessel dissection was not corroborated by the DART,[4] the ERBAC,[5] the STRATAS[6] or CARAT trials[7] or a meta-analysis of multiple trials published by Bittl.**

✓**The initial tide of enthusiasm was then supplanted *by a severe decrease in the rate of utilization of this procedure* almost to the point where emerging fellows from interventional training programs are reluctant to use the Rotablator, since they have had minimal exposure to it.**



By 2003–2004, the rate of rotational atherectomy use in the U.S. as reported by the ACC-NCDR and in Europe was ≤ 5%.

The Dark Side of Adjunctive Rotational Atherectomy

- ✓ **Cost** (It is an expensive device)
- ✓ Time
- ✓ **Technically challenging** (There is the myth of a "difficult" procedure)
- ✓ **Training** (Rotablation has a learning curve)
- ✓ Need familiarity with device and experienced operator
- ✓ Complications
- ✓ Injury Extension and Geographical Miss
- ✓ RCT's were not able to proof any advantage of Rotablation versus POBA (ERBAC[1997], SPORT[2000], ARTIST[2001])

High-speed rotational atherectomy with the Rotablator system has an unique characteristic compared with other atherectomy devices.

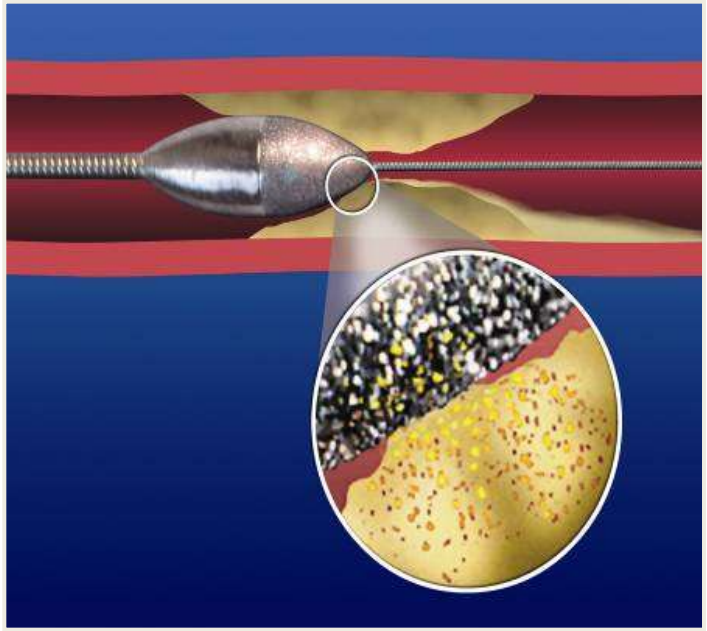

✓It removes plaque by abrading the atherosclerotic material, producing millions of microparticles which are smaller than red blood cell.

✓These microparticles are dispersed into the distal coronary circulation and are cleared by reticulo-endothelial system in liver, lung, and spleen.

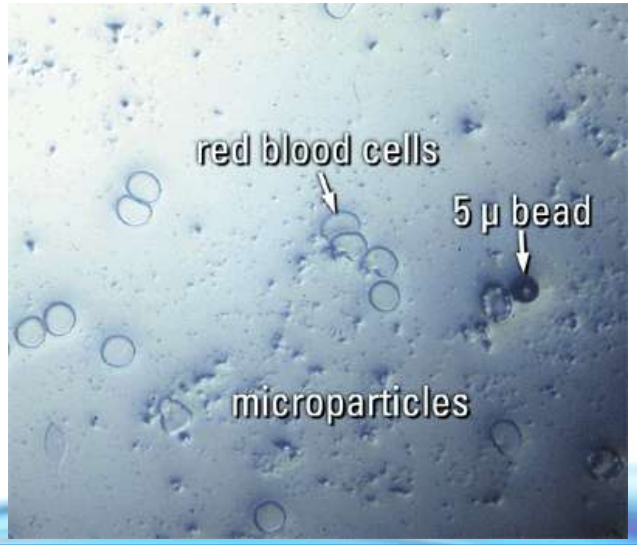

Differential atherectomy

Differential cutting means the ability to remove hard (inelastic) tissue while sparing soft (elastic) tissue which can deflect away from the advancing rotating abrasive burr.

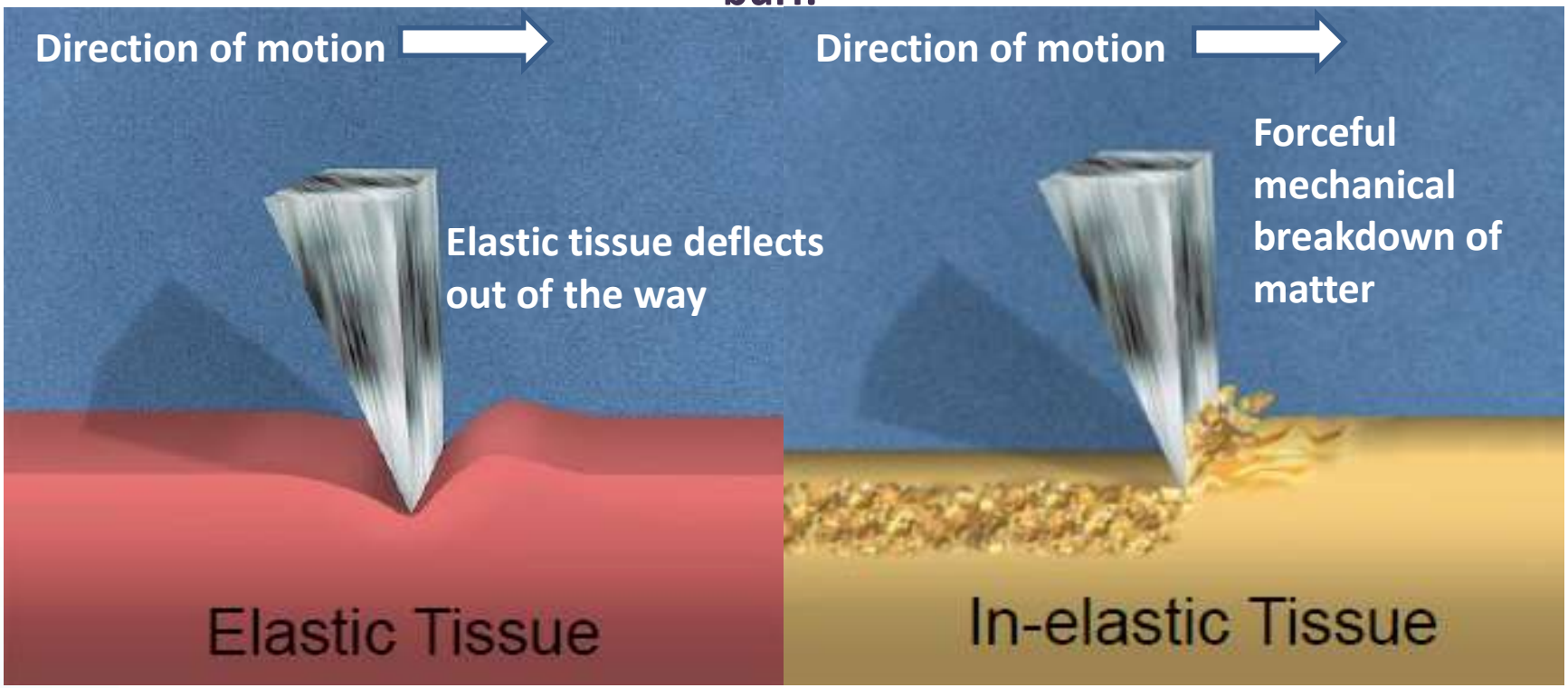

Helpful analogies:

- Shaving
- A nail file

According to this principle, the burr preferentially abrades hard and even calcified atherosclerotic plaque while deflecting the normal tissue, which is soft and elastic.

Orthogonal displacement of friction

Provides easy passage of the burr through tortuous and diseased segments of the coronary tree.

- ✓Friction is minimized by a sliding motion perpendicular or orthogonal to the contact surface
- ✓The faster something is turned the more the friction is reduced

Removal of cork from wine bottle. If a cork is twisted as it is pulled , the friction is reduced and the cork can be withdrawn easily

Helpful analogies

- Removing a cork from a champagne bottle
- Taking a ring off a finger

Rotablator: Benefits

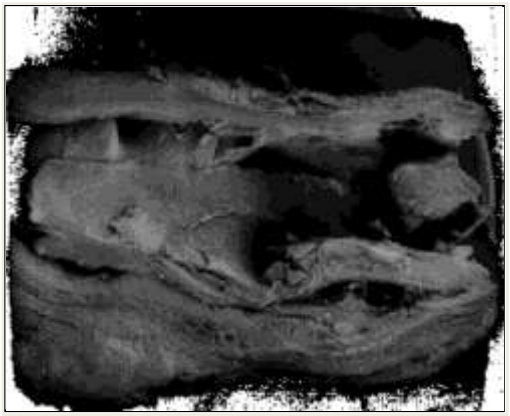

post-PTCA procedure



post-Rotablator® procedure (with minimal vessel injury)

- Minimises vessel wall stretch and elastic recoil
- Eliminates vessel barotrauma
- Removes all plaque morphologies; ***Soft, fibrotic, calcified***
- Produces a smooth lumen channel for improved hemodynamic flow
- Facilitate stent delivery and expansion

Hardware Components Overview

Console



DynaGlide™ foot pedal



Tank, regulators, attachments

Compressed air or nitrogen

Disposable Components Overview





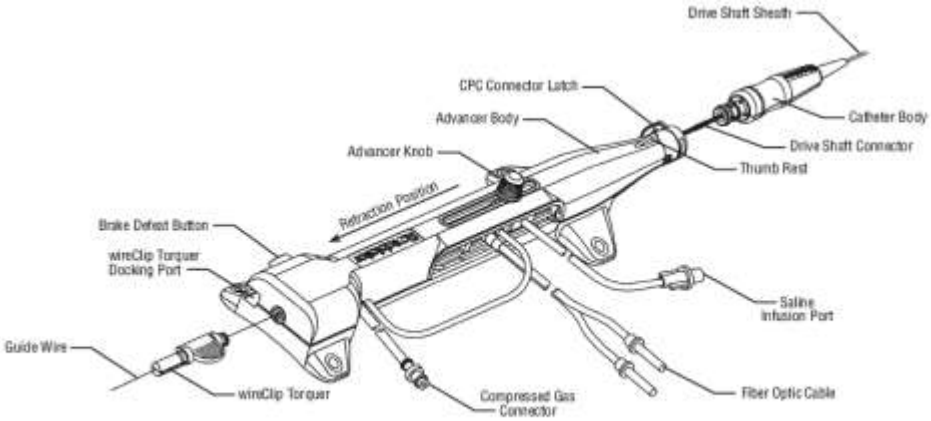

Figure 1
Rotablator Advancer

Rotalink™ Exchangeable Catheter



Catheter

- 135 cm in length
- Sheath is .058”/1.473mm

Burr

- Elliptical shaped with 2,000 to 3,000 microscopic diamond crystals on the distal edge. The proximal surface of the burr is smooth
- The brass burr is nickel coated
- The diamond crystals are 20 microns in size, with only 5 microns extruding from the nickel coating
- Various sizes: 1.25, 1.5, 1.75, 2.0, 2.15, 2.25, 2.38, 2.5 mm

Burr Size and Guide Selection

Burr diameter Mm	Burr diameter Inches	Recommended guide catheter (French)	Minimum ID required (Inches)
1.25	0.049	6.0	0.060
1.50	0.059	6.0	0.063
1.75	0.069	7.0	0.073
2.00	0.079	8.0	0.083
2.15	0.085	8.0	0.089
2.25	0.089	9.0	0.093
2.38	0.094	9.0	0.098
2.50	0.098	9.0	0.102

- Guide catheter with side holes
- Guide catheter that provides coaxial engagement will reduce unfavorable guidewire bias
- Guide catheter to accommodate the final burr size to be utilized

*Recommended Curves**

Left	Right
Q Curve®	FR4
CLS™	Multi-purpose

* Avoid abrupt primary and secondary curves.

Guide wire bias (divergence from the central axis of the vessel)

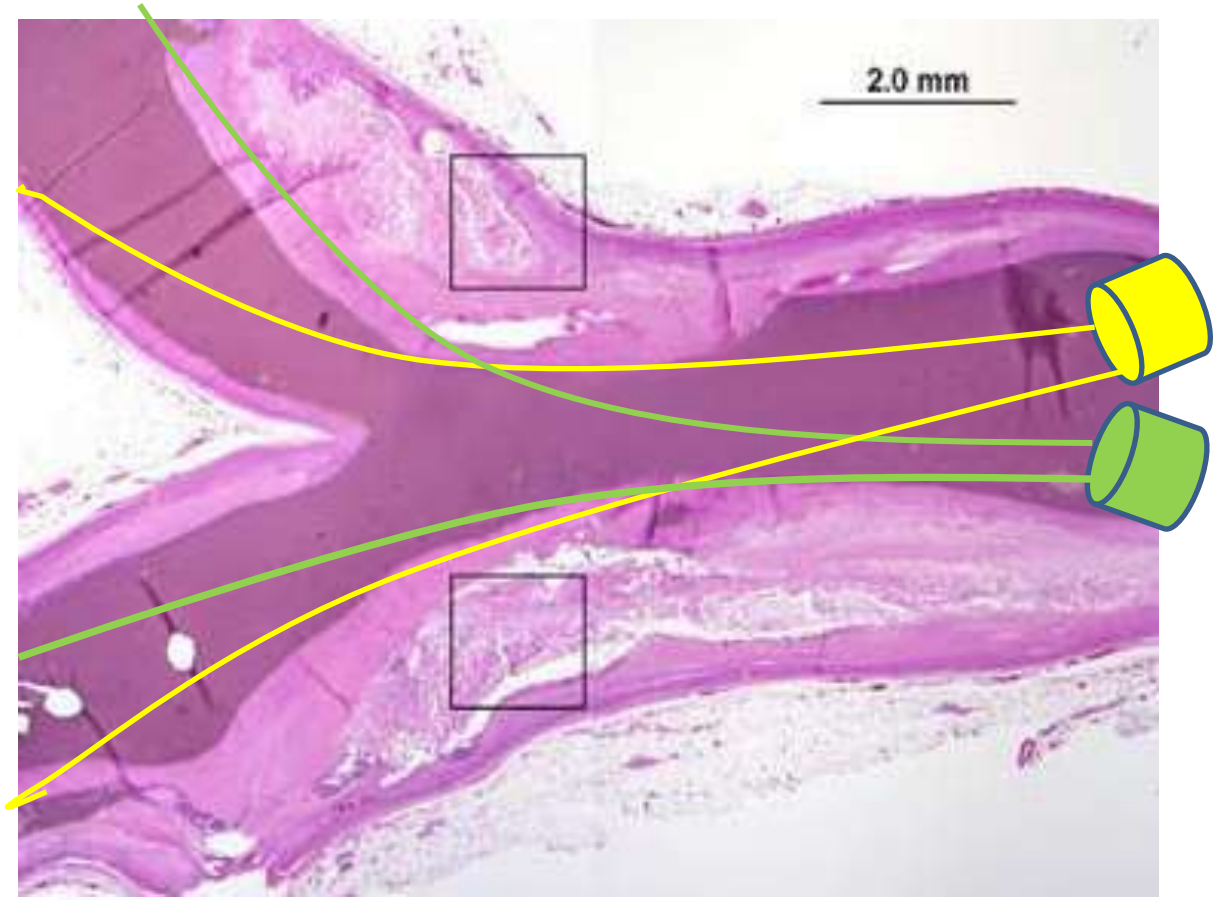

Assess different guide catheters and possible positions of the guide catheter and the impact on the guidewire

The guidewire placement plays an important role in the efficiency of debulking

Rotawire™ Floppy and Extra Support Guide Wire



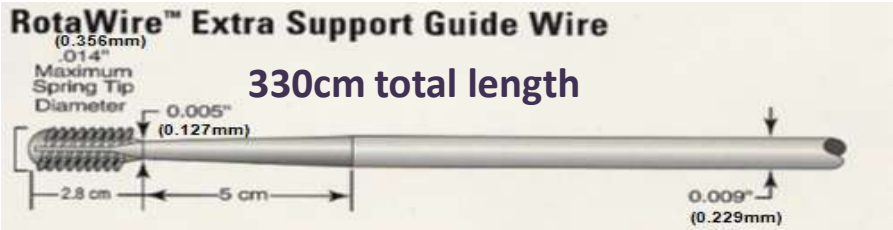

- Flexible and torqueable to enhance navigation
- Significantly reduced guidewire bias
- Short Spring Tip (2.2cm)
- Light rail support

- Spring Tip (2.8cm)
- Lead wire for those physicians requiring a "stiffer" wire

A stiffer GW dose not always produce an unfavorable bias but sometimes makes favorable bias which may help a sufficient ablation of angulated heavily calcified lesion.

Use more frequently microcatheters for wire exchange

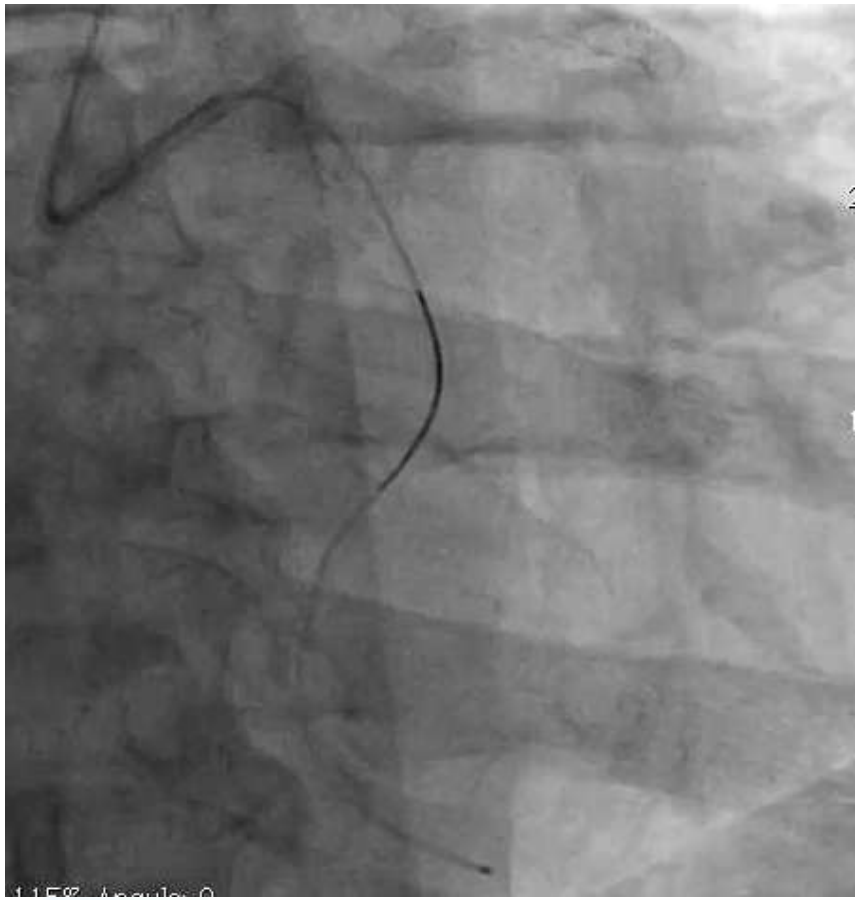

In cases where the rotawire cannot be advanced, past the lesion a conventional angioplasty wire with an exchange microcatheter can be used. The rotawire can be advanced and positioned distally.

***** Finish the intervention on a normal wire**

Advancing the burr

✓ ***Nonactivated burr*** **advancement-reaching the platform segment**

✓ ***Activated burr advancement***

To reach the platform segment, low-speed (100- 120000 rpm) can be used to minimize ablation. The whole system can be advanced by defeating the brake and holding the wire.

✓ ***Dynaglide is not recommended for advancement*** **because the rotational speed does not fall when resistance is met.**

Dynaglide is a control that sets the rotation speed of the rotablator at 50.000-90.000 rpm and is used for reducing friction when removing the device.

Ablating Technique

Proper: Slow/Smooth/Short

Feedback During Ablation

- **Visual**
- Smooth advancement under fluoroscopy
- Contrast injection to discern lesion contours and borders
- **Auditory**
- Pitch changes relative to resistance encountered by burr
- **Tactile**
- Advancer knob resistance
- Excessive drive shaft vibration: excessive load on burr advanced too rapidly

ROTATIONAL ATHERECTOMY PROTOCOLS

What is my concept of "rotablating a lesion"

To debulk plaque?

or

To modify plaque?

ROTATIONAL ATHERECTOMY PROTOCOLS

Different protocols for rotational atherectomy have been investigated in an attempt to obtain the highest acute and at long-term success rate with the lowest risk of procedural complications

Particular attention has been paid to:

- **Burr size (burr to artery ratio)**
- **Rotablation speed**
- **Motion pattern of the burr**

ROTATIONAL ATHERECTOMY PROTOCOLS

Burr selection is dependent on the treatment strategies with Rotablator.

- ***PRIMARY THERAPY:*** **Maximal safe debulking with no further adjunctive treatment.** ***Burr/Artery ratio 0.75-0.85/1***

- ***LESION MODIFICATION:*** **Improving lesion/vessel characteristics (compliance) in order to allow adjunctive technologies (DCA, PTCA, Stent).** **Burr/Artery 0.6-0.7/1**

STRATAS Study To Determine Rotablator And Transluminal Angioplasty Strategy

Routine strategy (plaque modification) is better than aggressive debulking.

500 patients

Agresive
Burr/artery ratio of 0.80 - 0.85
with or without ≤ 1 ATM PTCA

Routine
Burr/artery ratio of 0.70 - 0.75
Adjunctive PTCA ≥ 4 ATM

Results:	Routine	Aggressive
Procedural results:		
Max. Burr size (mm)	1.8mm	2.1mm
Burr/artery ratio	0.71	0.82
Burrs used	1.9	2.7
Acute results:		
final MLD	1.97	1.95mm
residual stenosis	26%	27%
clinical success	93.5%	93.9%
CK-MB rise >5 x nl	7%	11%
6 month results:		
TLR	22%	31%
MLD	1.26mm	1.16mm
loss index	0.54	0.62
angiographic restenosis	52%	58%

Rotablator has been newly re-defined as a tool for:

- modification of a plaque
- improving the plaque and vessel compliance
- better performing PCI in difficult situations

ROTATIONAL ATHERECTOMY PROTOCOLS

stepped burr approach vs. single burr approach

- **Bigger burrs may debulk more of the lesion but they also may damage/activate more blood cells.**

- **Starting with smaller burrs reduces the plaque burden to the distal bed and a patent lumen is achieved in a shorter period of time**

- ***A RotA technique with 2 burrs*** **may be chosen in order to reduce the incidence of the no-reflow phenomenon. The smaller burr (usually 1.25 mm) is used first, followed by a larger burr based on the size of the vessel, aiming at a burr/vessel ratio *that does not exceed 0.6-0.7*. However sometimes a single small burr is sufficient.**

ROTATIONAL ATHERECTOMY PROTOCOLS

***The atherectomy speed must be approximately 140000 rpm*,**
although there is no clear cut-off and some operators use 150,000 rpm.
(may be beneficial for the reduction of slow flow or no reflow)

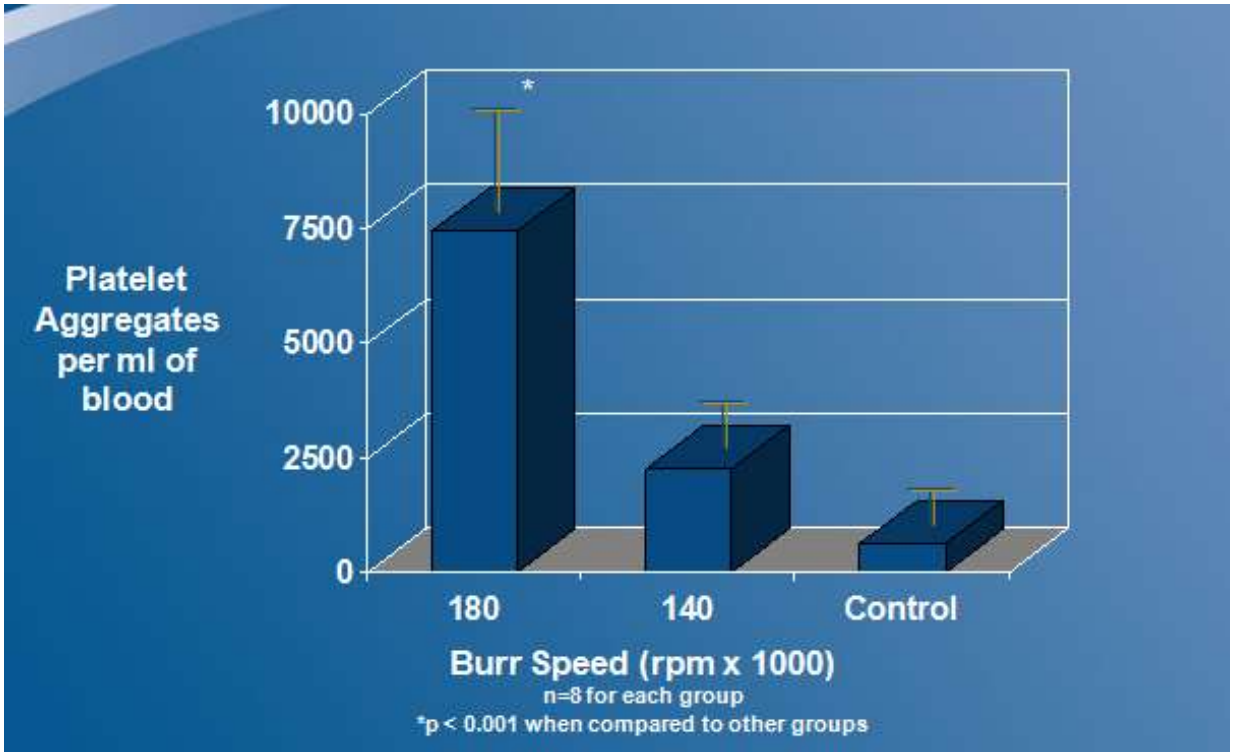

The higher the rotational speed, the more platelets are activated

Motion pattern of the burr

Do not push the rotablator into the lesion. **The intermittent application of RotA within lesion is preferred;** ***Use "Pecking" technique***

"Pecking" technique is used, where the burr is moved forward and backward the lesion, avoiding crossing the entire lesion during the initial passage

"Pecking" **motion prevents "trenching" into arterial wall, allows wire to reposition as vessel compliance changes with debulking**

Time of runs 15"

Intermittent pull back for coronary perfusion and/or contrast injection

ROTAFLUSH - "COCKTAIL"

USE RotaFlush

CARAFE STUDY PILOT

Cocktail Attenuation of Rotational Ablation Flow Effects
Virtually eliminates "Slow Flow" and "No-Reflow" phenomenon when used with current technique modification:

- **During RotA, 500 ml of heparinised (5000 units) normal saline solution with 5 mg verapamil and 1000 μg nitroglycerine is administered locally, with a view *to preventing thrombus formation and vascular spasm, and avoiding the no-reflow phenomenon.***

Other cautions in Ablating Technique

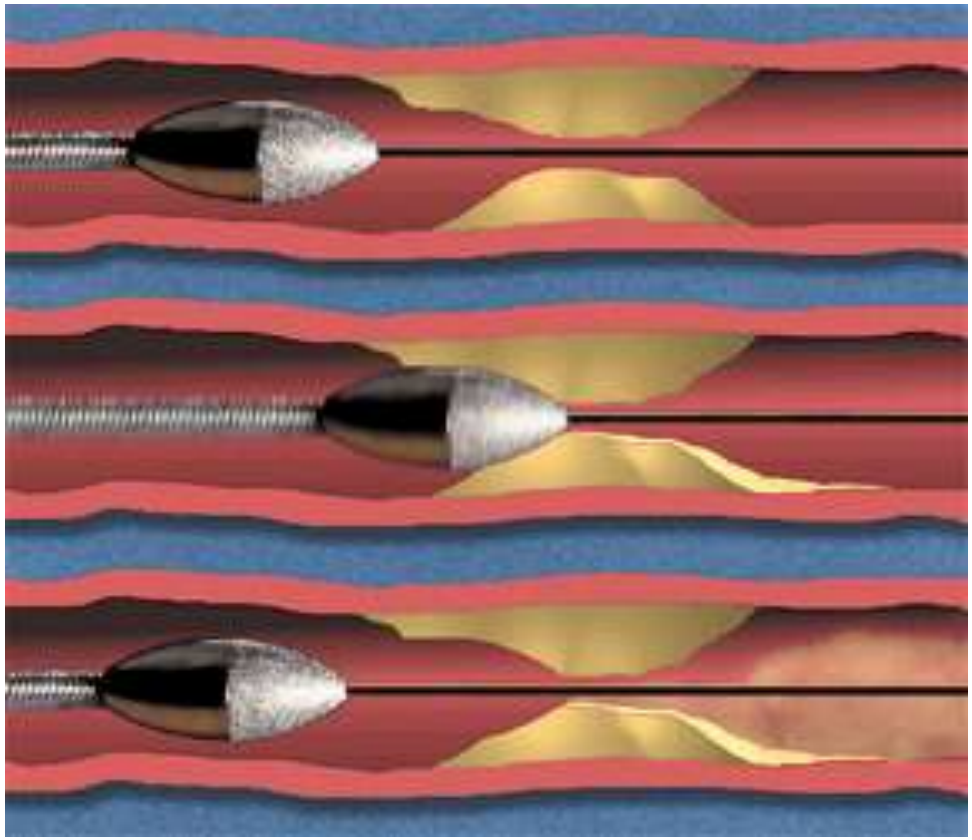

- ***During the ablation, excessive deceleration (more than 5,000 rpm) must be avoided*** **because it results in improper ablation and increases the risk of vessel injury, the formation of large particles, and ischemic complications related to excessive heat generation**

Other cautions in Ablating Technique

- Avoid rapid advancement, dottering, force
- Avoid stopping or starting the burr in the lesion
- Avoid stopping burr distal to lesion
- Avoid adjusting rpm's during ablation

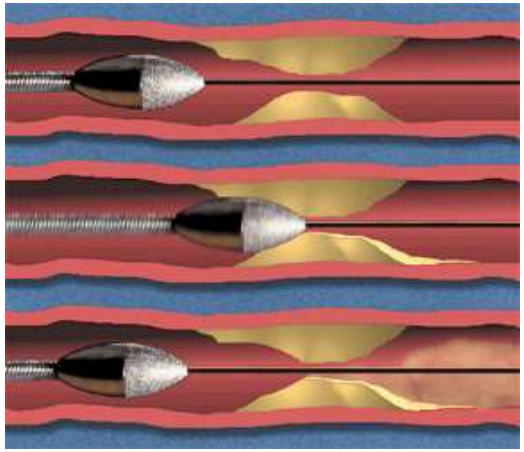

- Avoid the burr to remain in one location while rotating at high speeds

- Avoid burring in the guide catheter
- <u>Finish with one polishing run.</u>
  - No RPM drop
  - Little to no resistance

- ***As the indications for angioplasty grow with Drug-Eluting stents, so will the number of complex lesions to be treated***
  - Calcified lesions
  - Long & diffuse disease
  - Small vessels
  - Bifurcations
  - Multi-vessel disease



- **Number of patients sent for CABG may decrease**

Do We Need Rotablator?

The Rotablator is mainly used to improve procedural success rate in heavily calcified lesions

Calcified Lesions
Can somebody help me?

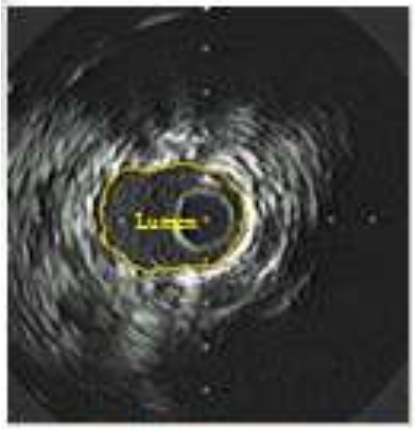

Stent Deployment in Heavily Calcified Vessel

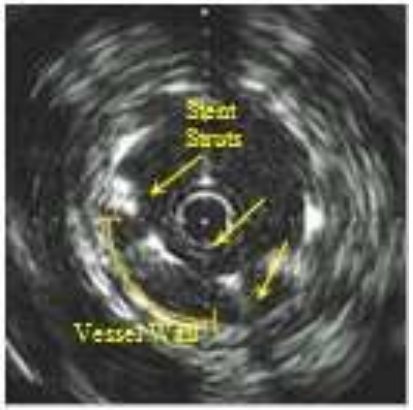

Unapposed Stent

The prevalence of severe calcium, defined as superficial in nature with greater than 180° arc, is estimated to present itself in 12% of cases using angiographic imaging. When IVUS guidance is used, it's seen in approximately 26% of cases.

Achieving optimal stent expansion is a crucial fact for both acute outcomes and restenosis rates

Heavy calcification increases the risk of incomplete stent expansion

- **Asymmetrical stent expansion occurs in up to 50% of cases where calcium is not treated before stent deployment**

The Rotablator is mainly used to improve procedural success rate in heavily calcified lesions

✓**The rate of failure to reach the target site within the coronary artery with the stent increases from 1.8% in non-calcified lesions up to 5.8% in heavily calcified vessels.**

✓**Rotablator through plaque/lesion modification and improvement of arterial compliance allows the passage of balloons and stents, facilitates a more uniform and symmetrical stent deployment.**

✓***In heavily calcified lesions procedural success rate with RA ranges from 89 to 98%***

Rotablator Enables You To Treat Calcified Vessels Effectively and facilitates GREAT RESULTS

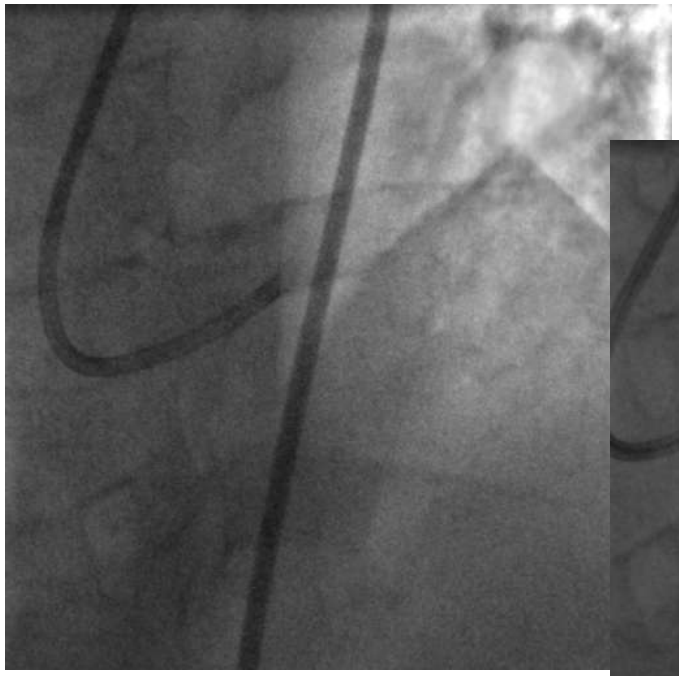

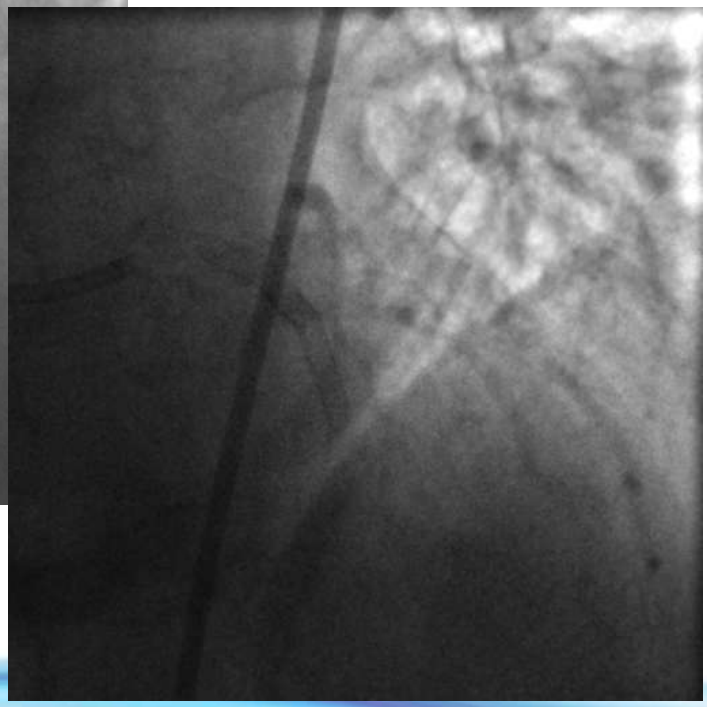

Theoretically, RA and DES could act synergistically in complex lesions

Device Synergy

DES

- Plaque compression
- Scaffolding support
- Prevents elastic recoil
- Achieves larger MLD
- Smooth lumen
- Suppress neointimal proliferation

Rotational Atherectomy

- Pulverizes plaque
- Effective in calcified lesions
- Changes lesion compliance
- Decreases plaque shifting

Rota-DES

- Full stent expansion and deployment
- Decrease subacute thrombosis
- Better MLD
- Decrease restenosis and TLR

EuroIntervention. 2009 Aug;5(3):370-4.

Rotational atherectomy followed by drug-eluting stent implantation in calcified coronary lesions.

Furuichi S, Sangiorgi GM, Godino C, Airoldi F, Montorfano M, Chieffo A, Michev I, Carlino M, Colombo A.

96 patients

The rate of target lesion revascularisation (TLR) was 9.5%.

CONCLUSIONS: RA followed by DES implantation in severely calcified coronary lesions appears to be feasible including high rate of procedural success and low-incidence of TLR considering this complex lesion subset.

J Invasive Cardiol. 2011 Jan;23(1):28-32.

Drug-eluting stents following rotational atherectomy for heavily calcified coronary lesions: long-term clinical outcomes.

Benezet J, Díaz de la Llera LS, Cubero JM, Villa M, Fernández-Quero M, Sánchez-González A.

102 consecutive patients

The combined endpoint occurred in 12.7% of cases.

CONCLUSION: DES following rotational atherectomy for heavily calcified coronary lesions is a safe and effective procedure that provides good long-term clinical outcomes.

Hellenic J Cardiol. 2011 Sep-Oct;52(5):399-406.

The use of rotational atherectomy and drug-eluting stents in the treatment of heavily calcified coronary lesions.

Dardas P, Mezilis N, Ninios V, Tsikaderis D, Theofilogiannakos EK, Lampropoulos S.

184 patients

major adverse cardiac events was 14.85%.

CONCLUSIONS: The combination of RotA and DES in calcified coronary artery lesions has a very good angiographic result and a satisfactory clinical outcome.

Zhonghua Xin Xue Guan Bing Za Zhi. 2013 Jun;41(6):457-61.

[Safety and efficacy of rotational atherectomy followed by drug-eluting stenting for treating patients with heavily calcified coronary lesions].

[Article in Chinese]

Li Q, Liu J, Lu MY, Ma YL, Zhao H, Ding RJ, Liu CF, Wang WM.

65 cases

major adverse cardiovascular events13.8%

CONCLUSION: Rotational atherectomy followed by drug-eluting stent implantation is a safe and efficient technique for treating heavily calcified coronary lesions.

Catheter Cardiovasc Interv. 2013 Feb;81(2):285-91. doi: 10.1002/ccd.24367. Epub 2012 May 2.

Long-term clinical outcome of rotational atherectomy followed by drug-eluting stent implantation in complex calcified coronary lesions.

Abdel-Wahab M, Baev R, Dieker P, Kassner G, Khattab AA, Toelg R, Sulimov D, Geist V, Richardt G.

205 patients

the cumulative incidence of MACE (Kaplan-Meier estimate) was 17.7%.

CONCLUSION: This study represents the largest European data set of patients treated with RA in the DES era. RA followed by DES implantation in calcified coronary lesions appears to be feasible and effective, with a high rate of procedural success and low incidence of TLR and MACE at long term considering this complex patient and lesion subset.

However it should be emphasized that any reduction of restenosis *<u>might well have resulted from DES platform alone</u>* , while Rotablator may only contributed by allowing stent delivery and proper deployment

Controversy exists over whether rotablation should be performed due to the presence of severe calcifications in the coronary angiogram (primary rotablation) or only after failed conventional coronary intervention (secondary rotablation).

ROTAXUS

A Prospective, Randomized Trial of High-Speed Rotational Atherectomy Prior to Paclitaxel-Eluting Stent Implantation in Complex Calcified Coronary Lesions

.. to evaluate whether routine rotablation prior to DES implantation is more effective than the standard of care (balloon and DES) in the setting of complex calcified coronary artery disease.

ROTAXUS

240 patients enrolled between August 2006 and March 2010 at 3 clinical sites in Germany

1:1 randomization

Rota + PES (N=120)

PTCA + PES (N=120)

240 patients analyzed with complete in-hospital follow-up

- 2 patients died in-hospital
- 6 patients withdrew consent
- 5 patients lost at follow-up

Clinical follow-up at 9 months in 96.2% (N=227)

Angiographic follow-up at 9 months in 80.5% (N=190)

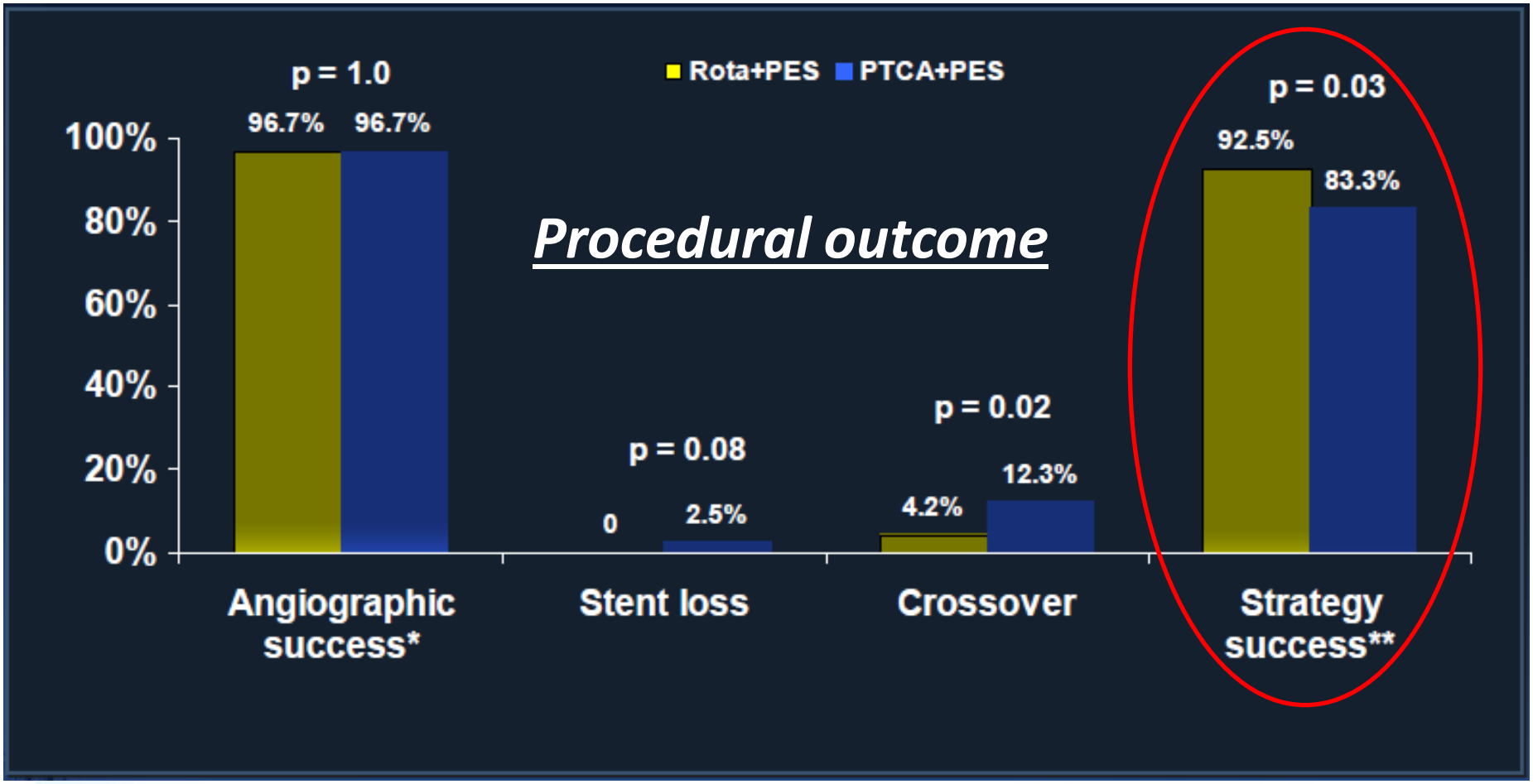
Procedural outcome
Rota+PES
PTCA+PES
100%
80%
60%
40%
20%
0%
p = 1.0
96.7%
96.7%
p = 0.08
0
2.5%
p = 0.02
4.2%
12.3%
p = 0.03
92.5%
83.3%
Angiographic success*
Stent loss
Crossover
Strategy success**

Primary Endpoint

In-Stent Late Lumen Loss at 9 Months

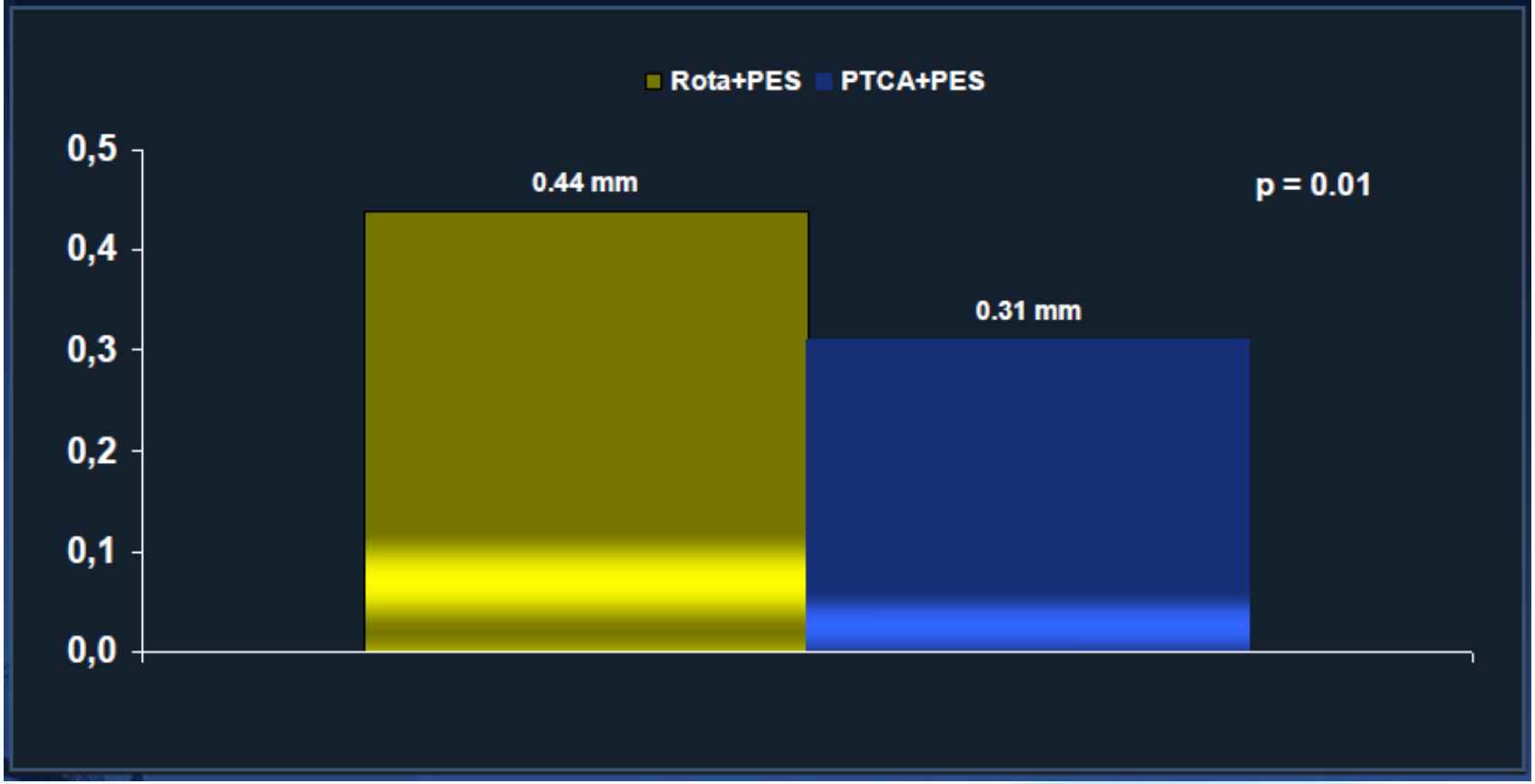

In-Hospital Outcome

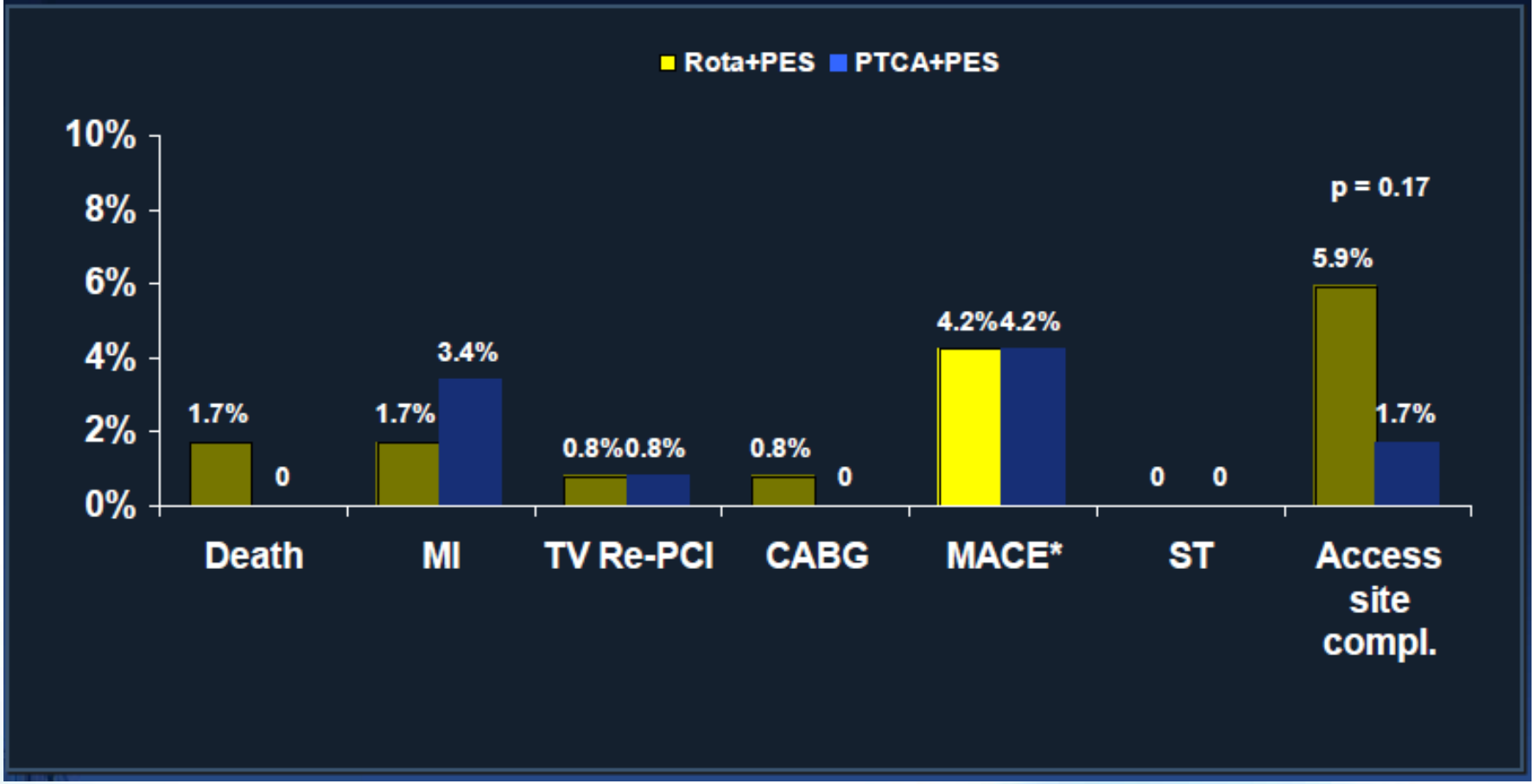

Events at Follow-Up

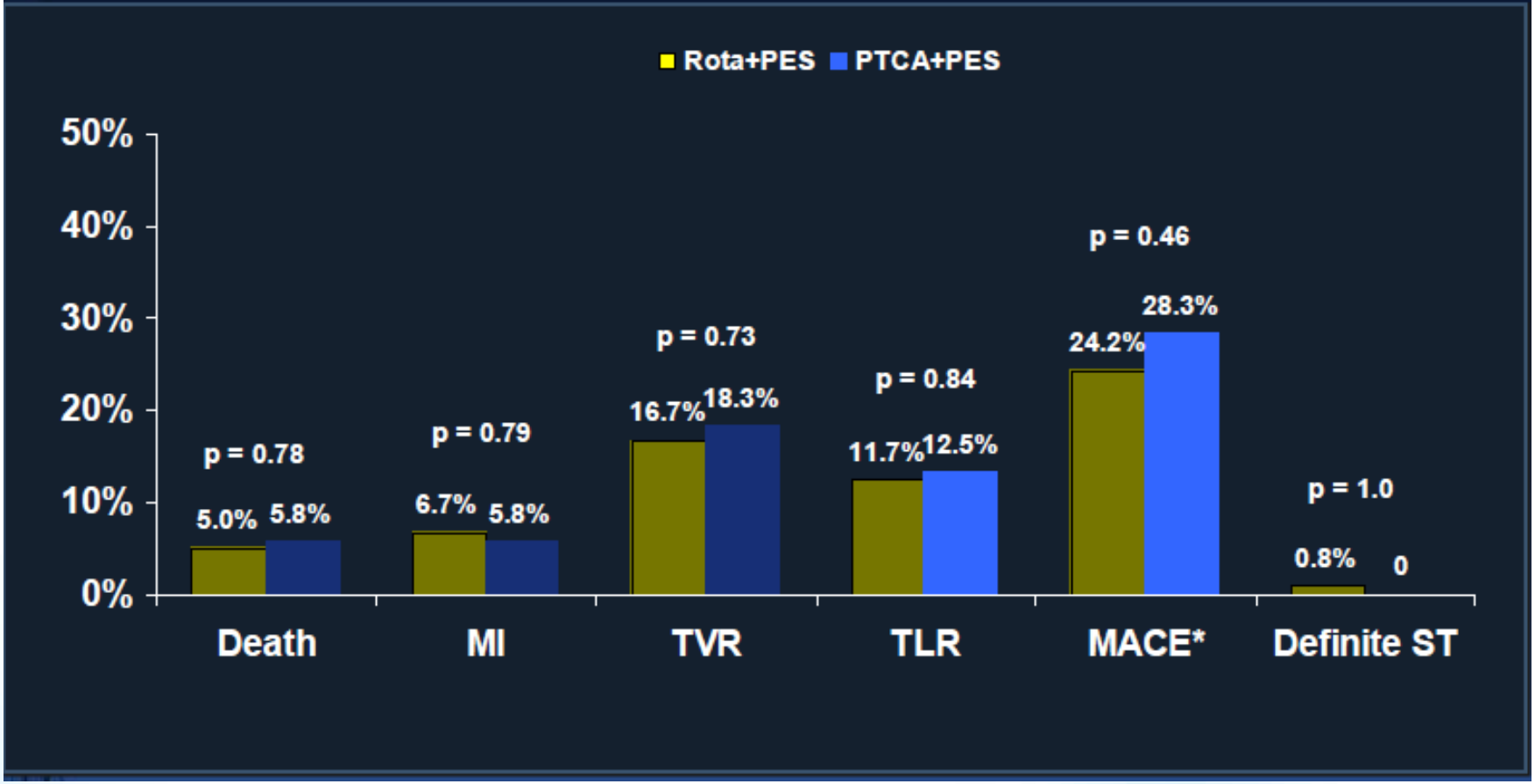

ROTAXUS-CONCLUSIONS

✓ **Although routine RA did not improve DES efficacy, RA remains an important tool for uncrossable or undilatable lesions and improves overall procedural success in this setting.**

✓ ***A strategy of balloon dilation with provisional rotablation before stenting should remain the default strategy for complex fibrotic/calcified lesions in the DES era.***

Rotational atherectomy of severely calcified coronary artery lesions: experience at Zurich University Hospital

Marietta Puck, Charlotte Regli, Stefan Toggweiler, Thomas F. Lüscher, Nils Kucher
Cardiovascular Centre, University Hospital Zurich

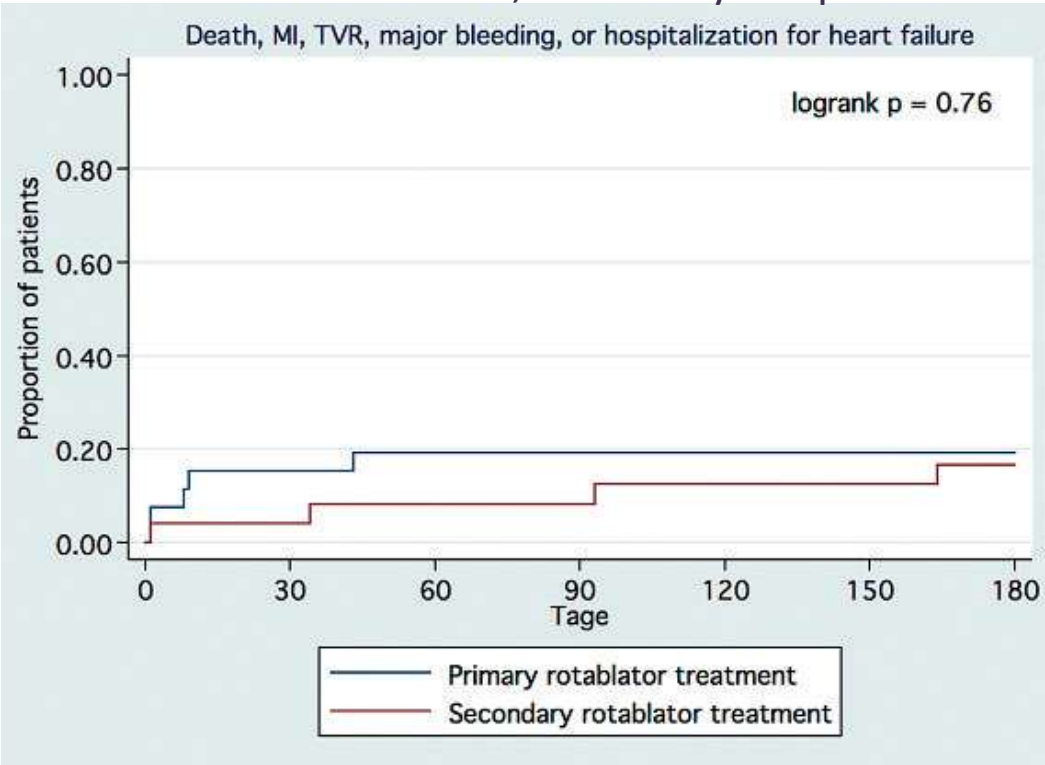

In patients with failed conventional intervention rotablation is feasible and associated with periprocedural complications and clinical outcomes at 6 months similar to those for primary rotablation.

European Heart Journal (2010) 31, 2501–2555
doi:10.1093/eurheartj/ehq277

ESC/EACTS GUIDELINES

Guidelines on myocardial revascularization

The Task Force on Myocardial Revascularization of the European Society of Cardiology (ESC) and the European Association for Cardio-Thoracic Surgery (EACTS)

Rotablation is recommended for preparation of heavily calcified or severely fibrotic lesions that cannot be crossed by a balloon or adequately dilated before planned stenting.	I	C

JUST DO IT ……. EARLY

The decision to use rotablation should be made early, before large dissections appear.

Can we with DES and balloons alone?

Rota-Rescue **defined as Rotational Atherectomy for:**

- ✓ **Inability to cross the lesion with the balloon**
- ✓ **Inability to completely inflate the balloon**
- ✓ **Inability to deliver a stent**

Rota-Rescue
Inability to cross the lesion with the balloon

✓ ***Failure to cross with a balloon*** **is a well recognised cause of failure to recanalise a CTO or calcified /tortuous vessels despite successfully positioning a guidewire into the distal true *lumen and accounts for 10%–15% of all procedure failures***

✓ **RotA is a safe and effective technique to overcome this frustrating situation**

✓ **Initiating treatment with the smallest burrs (1.25 mm) is the safest approach (subintimal tracking of the guide wire frequently created during CTO crossing-minimize the risk of vessel perforation).**

Rota-Rescue
Inability to cross the lesion with the balloon

We were unable to cross the lesion with a :

1.5 x 15 mm Maverick balloon

1.25X15 mm Ryujin balloon

1.25 mm over-the-wire Sprinter balloon and

0.85X10 mm NIC NANO balloon

6F Guideliner **catheter deeply into the RCA, just proximal to the point of the lesion**

Inability to cross the lesion with the same balloons

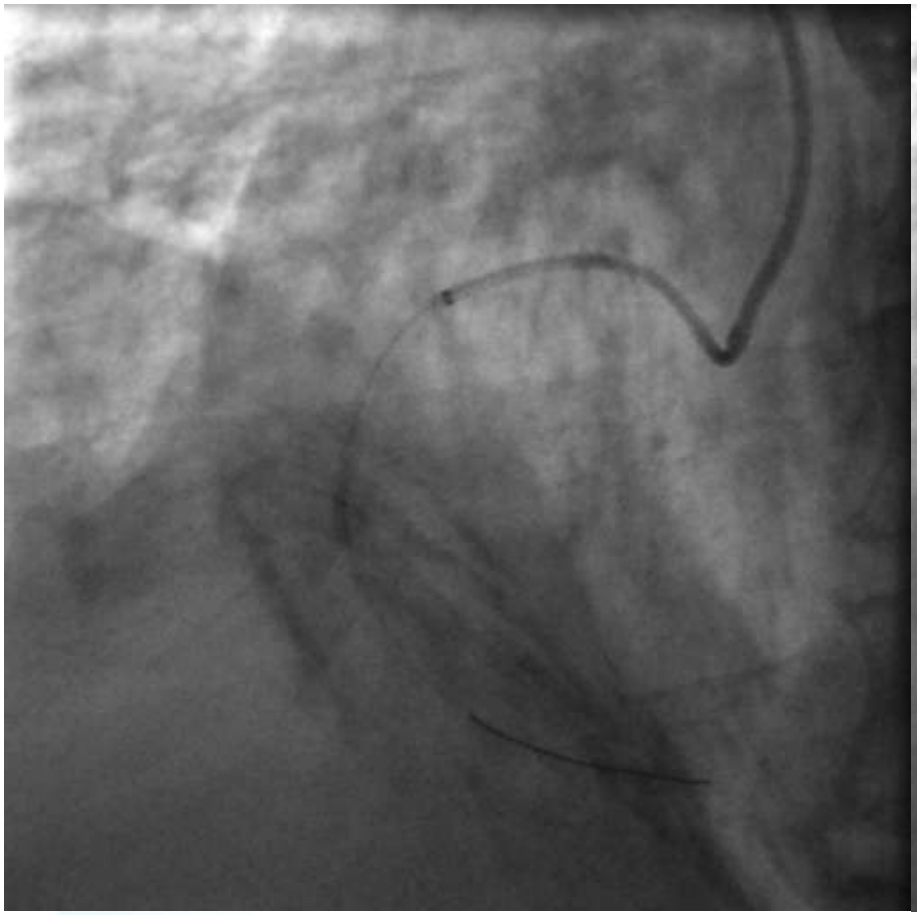

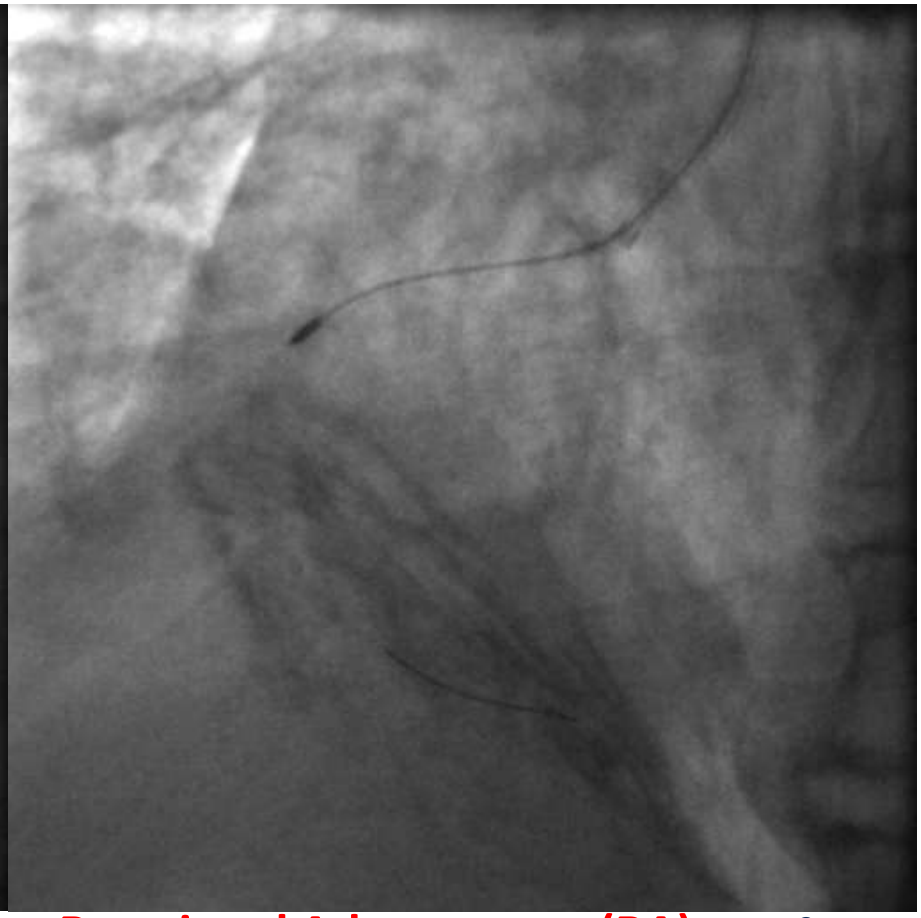

Rotational Atherectomy (RA) was first performed using a 1.25-mm Rotablator burr

Rota-Rescue
Inability to cross the lesion with the balloon

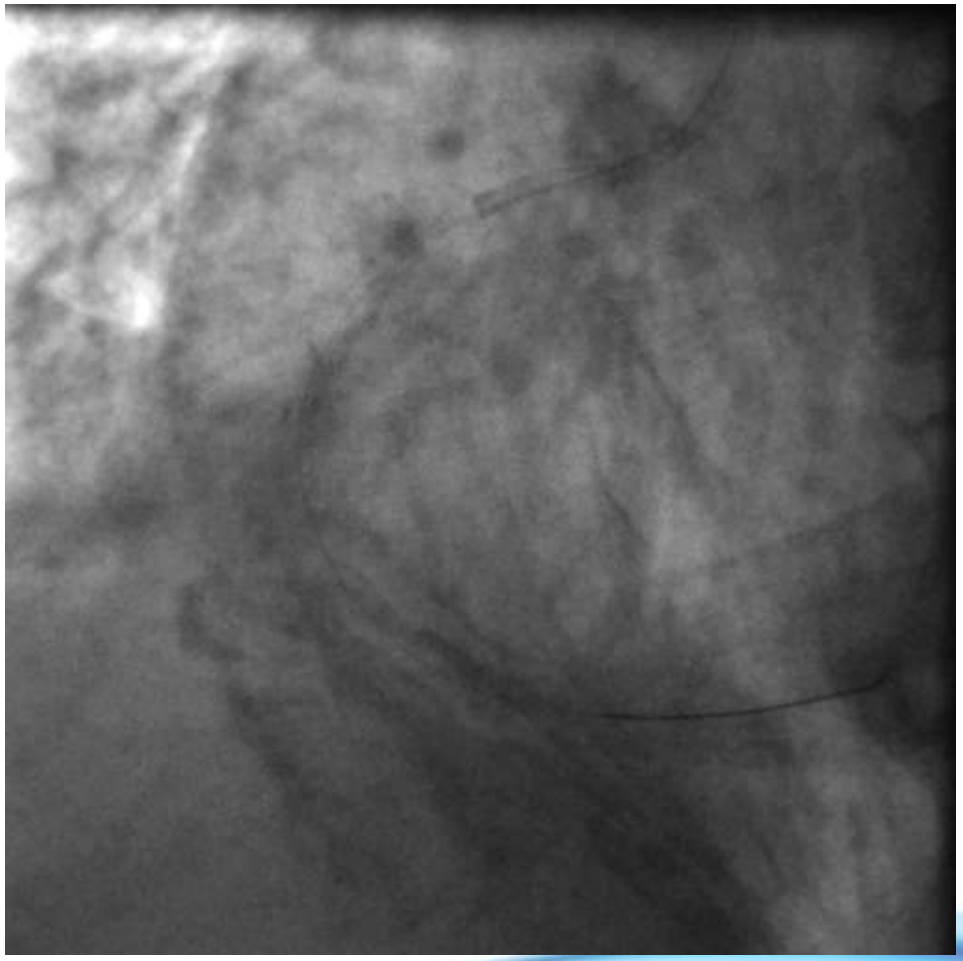

Rota-Rescue
Non Dilatable lesions

Rotablator Published Reports :Non dilatable lesions

Author	Lesion	N	Success (%)
Reisman (1993)	Non dilatable	34	97
Brogan (1993)	Non dilatable	41	90
Sievert (1993)	Non dilatable	32	97
Rosenblum (1992)	Non dilatable	40	97

W.C. Brogan et al. (Washington) *Am J Cardiol 1993;71:794-798*

n = 41 pts, 50 lesions in 8 immediately after balloon; in 33 on average 17 days (1-79)

Angiographic success: 98% (49/50) (1 elective CABG)

Procedural success: 90% (37/41)

MACE: 7% (3) 2 emCABG (1 death); 1 death day 14

Late clinical outcome: 7.2±3.4 months

MACE: 27% (5 re-PTCA; 2 CABG; 3 deaths)

Angio follow-up in 17 pts. (46%) – restenosis rate: 35% (6)

Rota-Rescue
Non Dilatable lesions

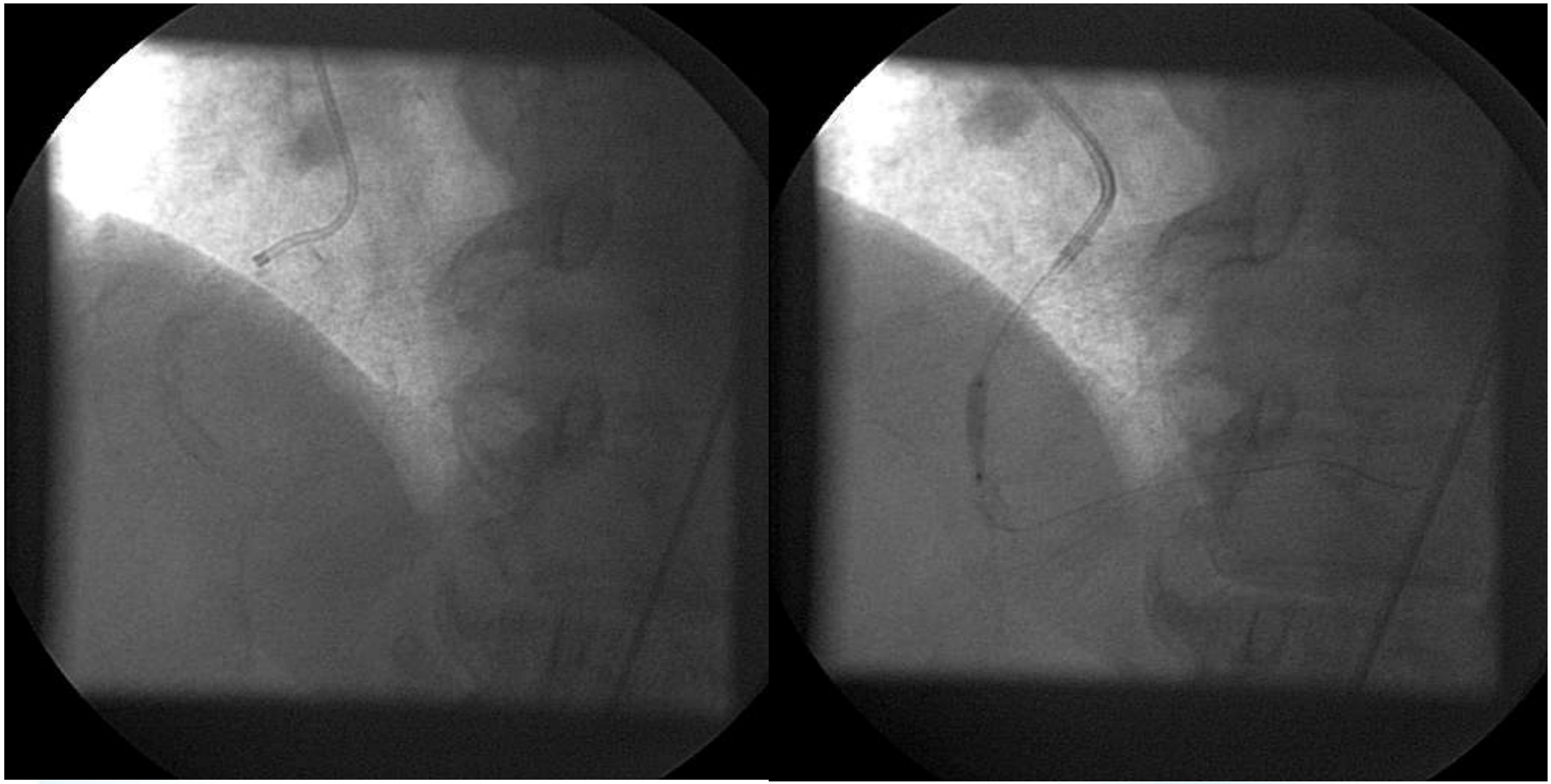

Rota-Rescue
Non Dilatable lesions

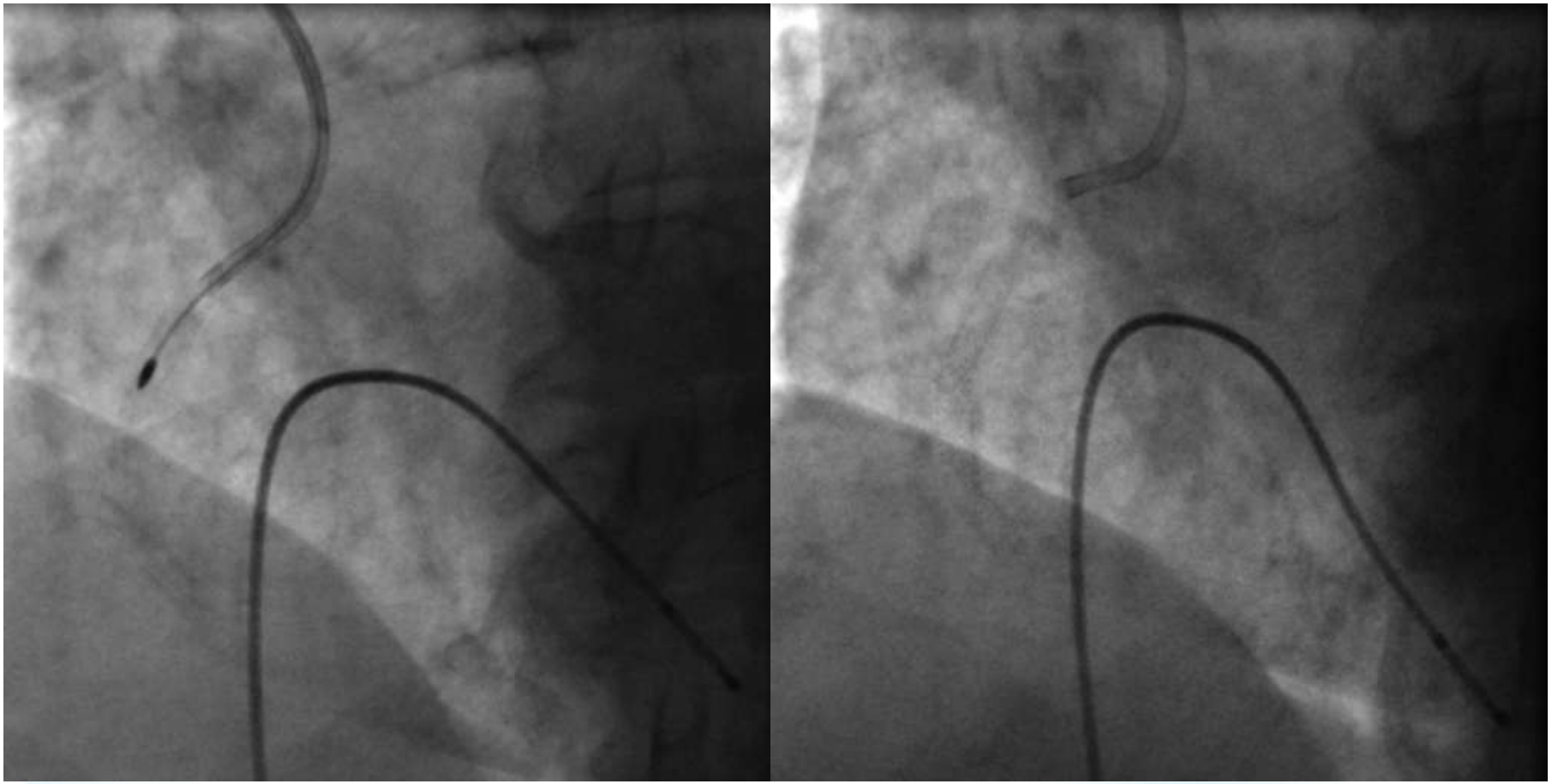

Rota-Rescue

Inability to deliver a stent

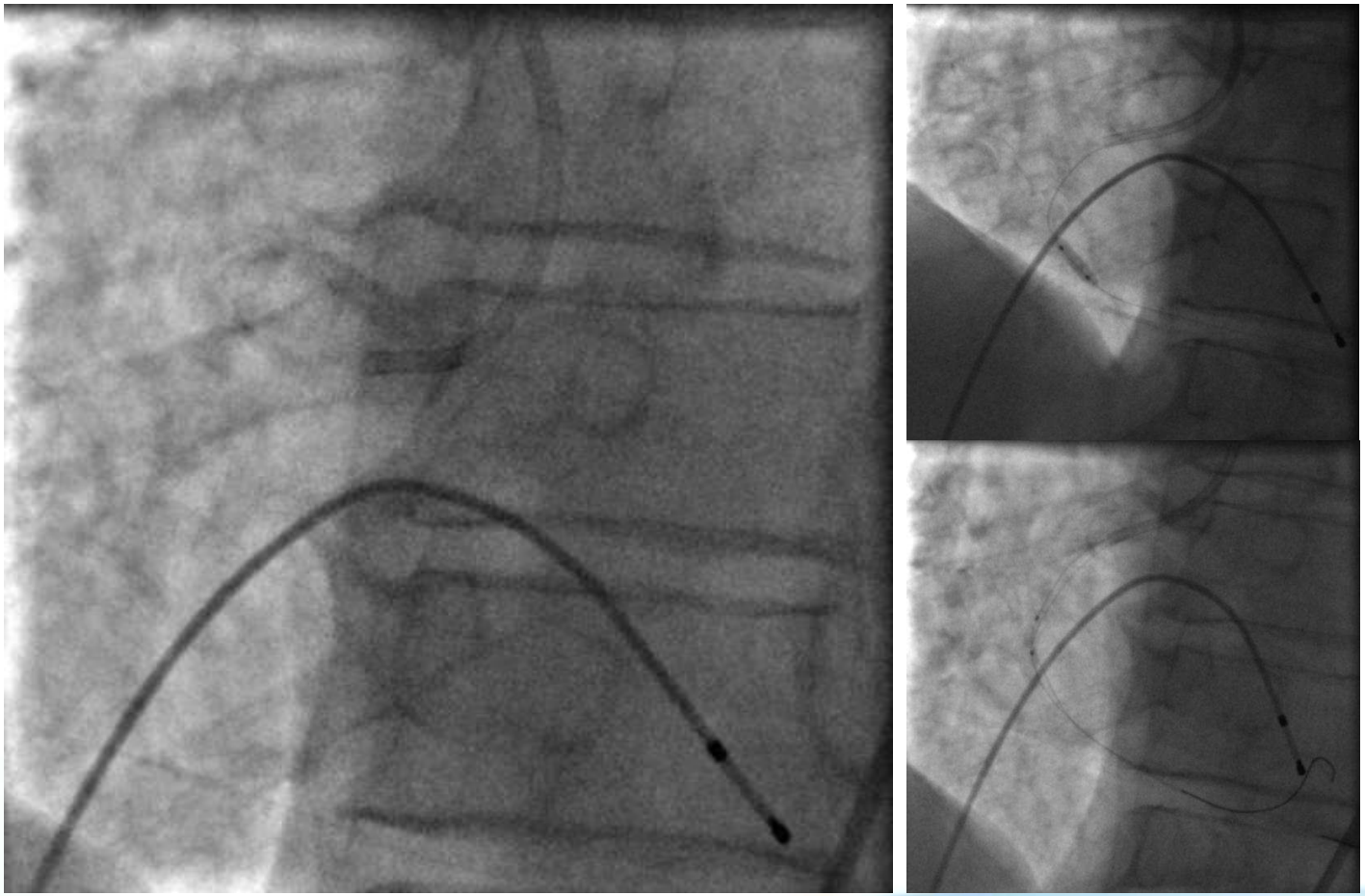

Rota-Rescue

Inability to deliver a stent

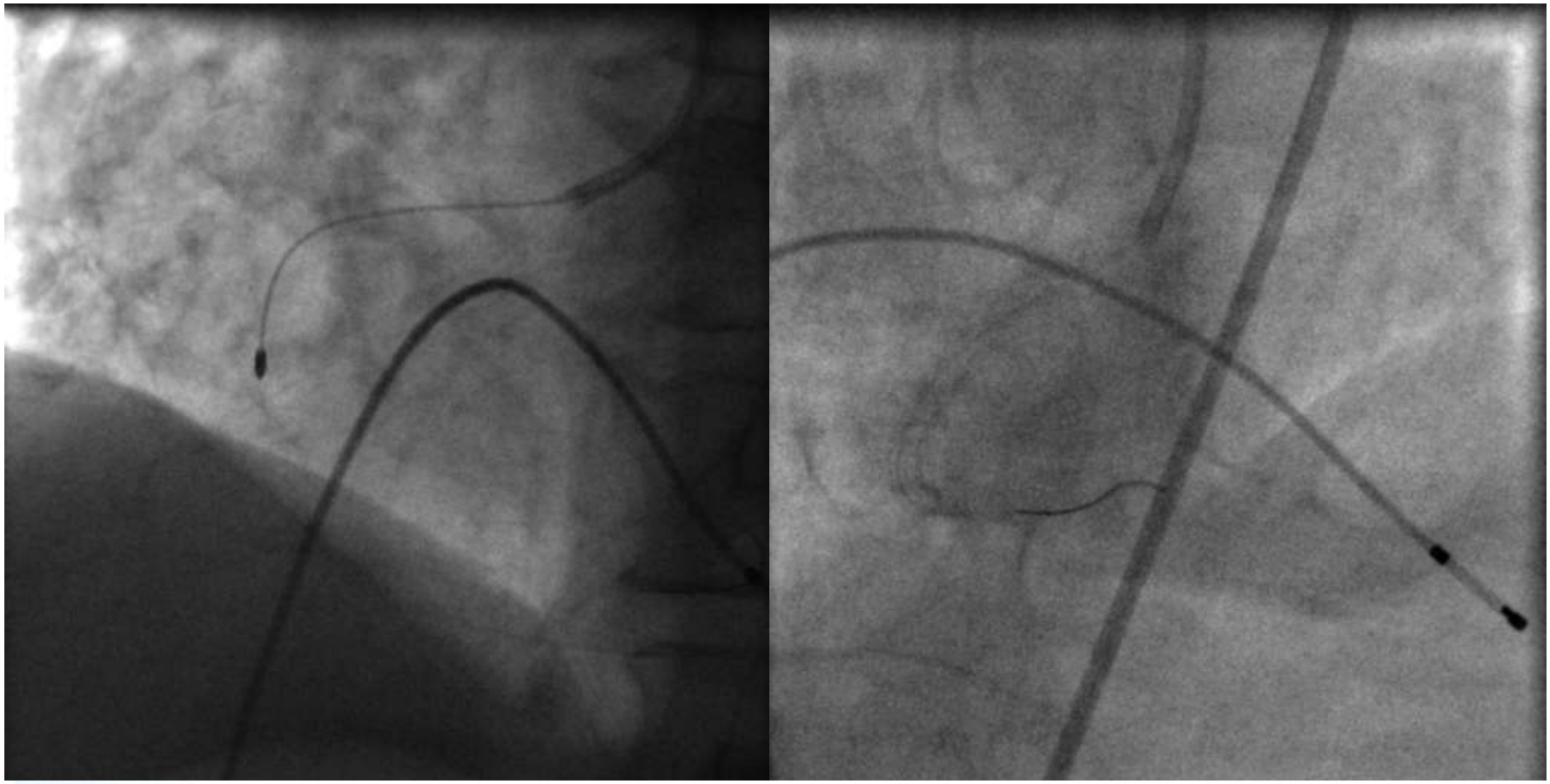

Rotablator: bifurcation lesions

Although not routinely applied in bifurcation lesions, rotational atherectomy of the main branch before stent implantation has been proposed to prevent plaque shifting in order to achieve side branch patency

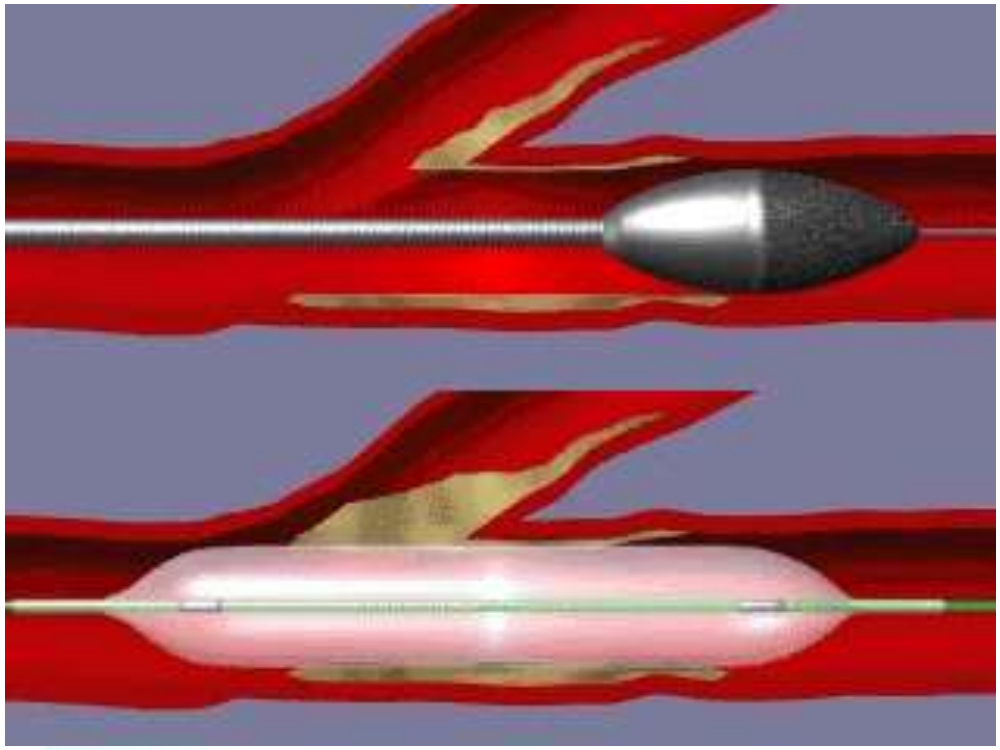

Use low burr-artery ratios (<0.5) especially when there is angulation present.

Rotablator: bifurcation lesions

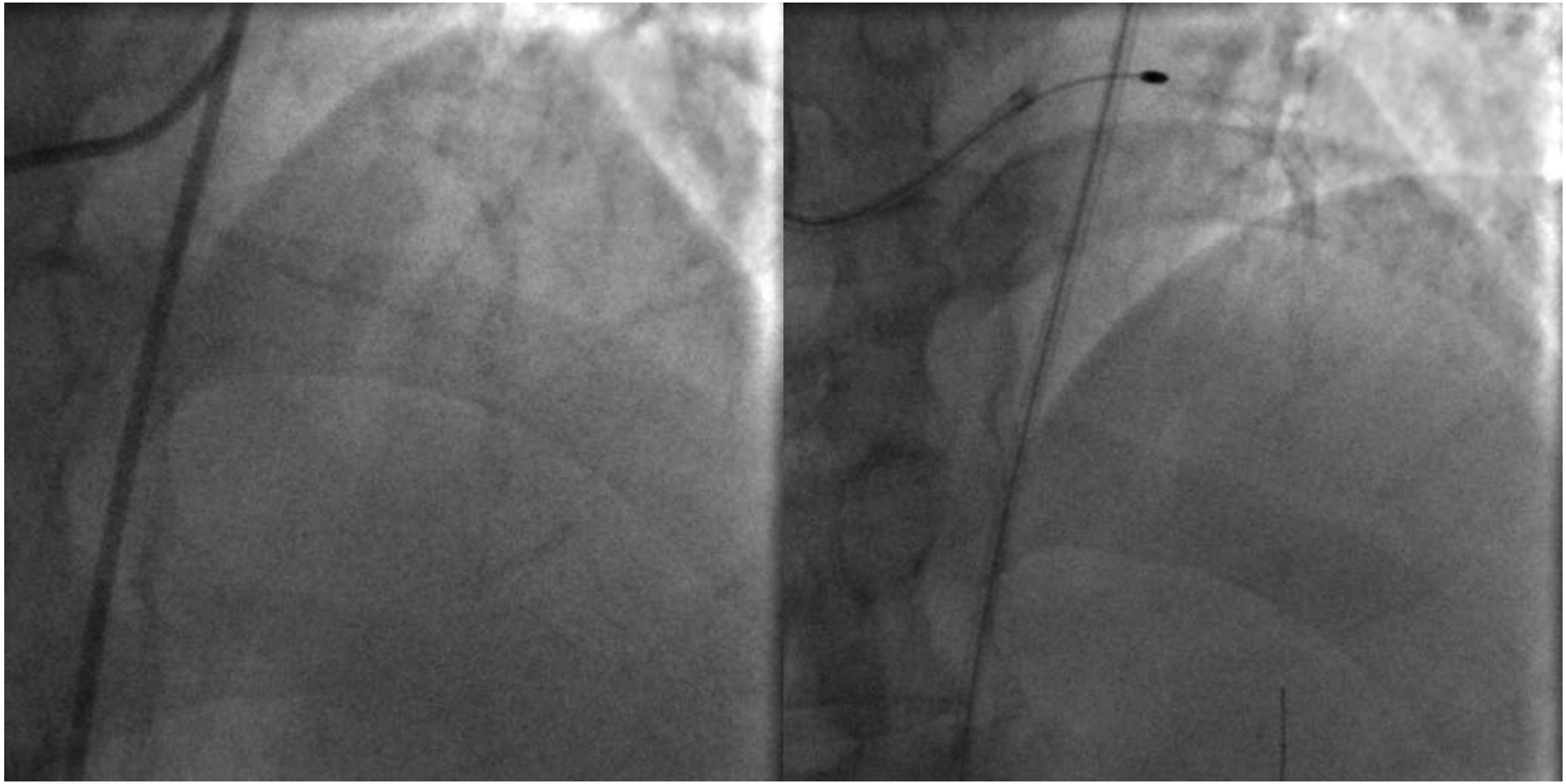

Rotablator: bifurcation lesions

It is essential to remember that wiring a side branch for side-branch protection during rotablation is not permitted as serious complication may occur

Rotablator :ostial lesions

In ostial lesions (specifically in RCA) the frequent fibrocalcific characteristics of these lesions make them well suited for rotablation treatment.

Author	lesion	N	Success (%)
Koller (1994)	Ostial	29	93
Zimarino (1994)	Ostial	69	92
Popma (1993)	Ostial	105	97

In ostial lesions, the success rate of the Rotablator procedure is > 90%

Rotablator :ostial lesions

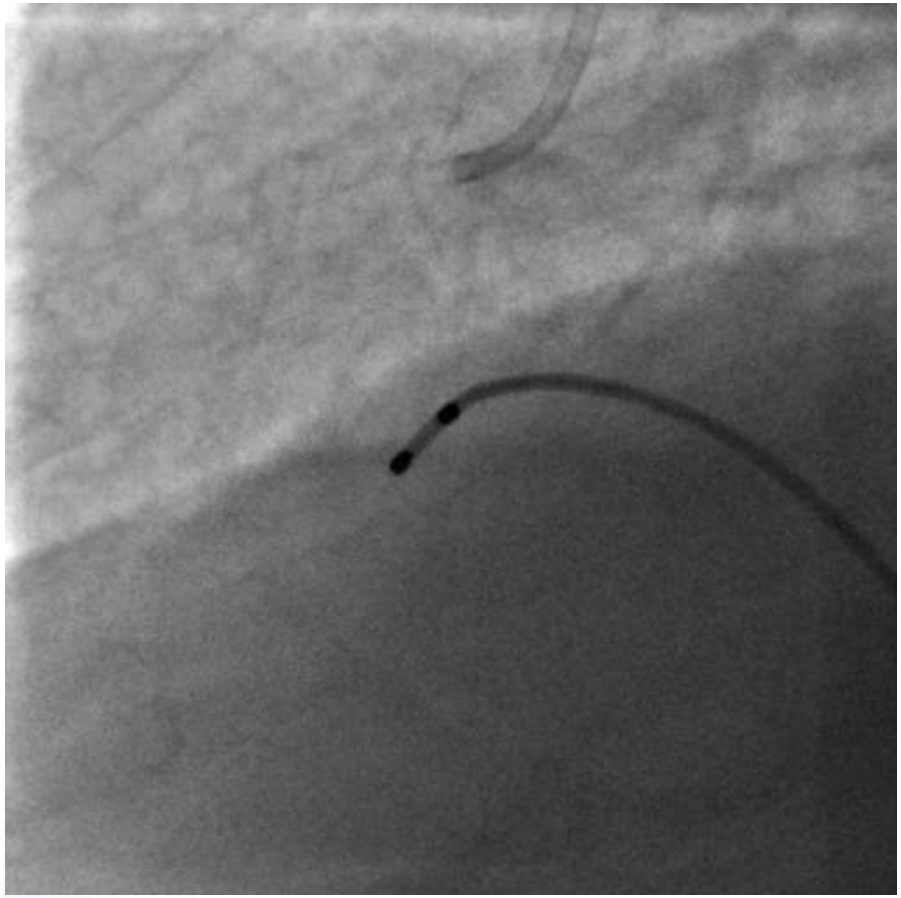

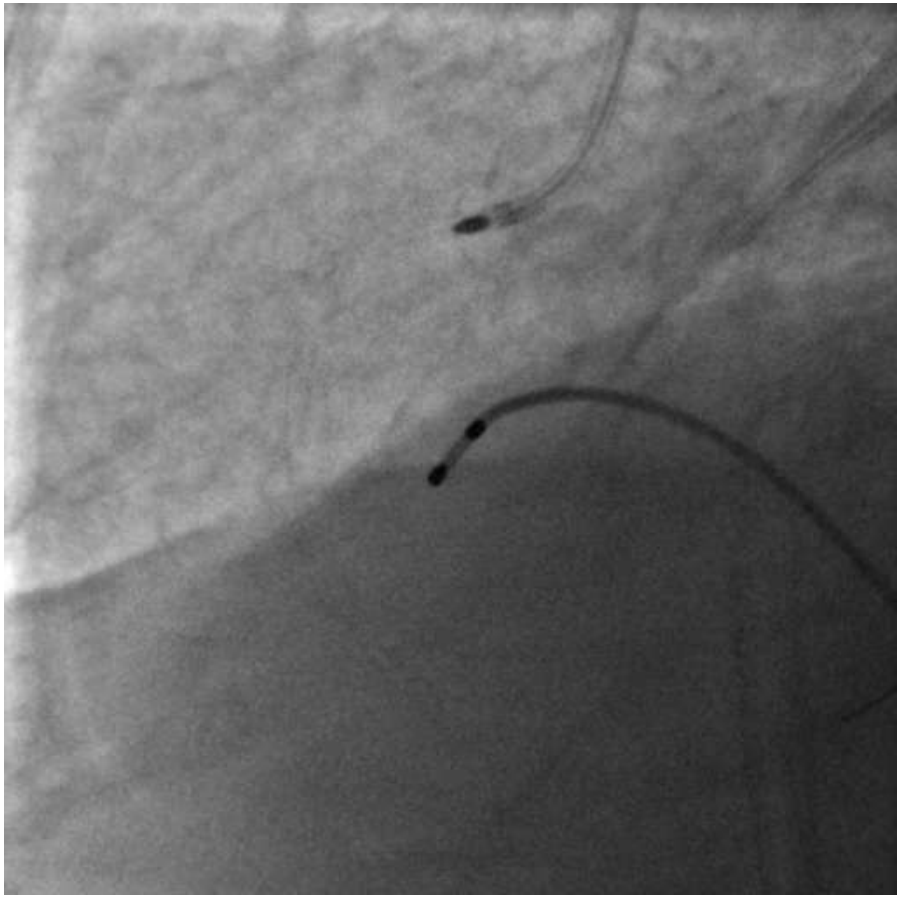

Rotablator :ostial lesions

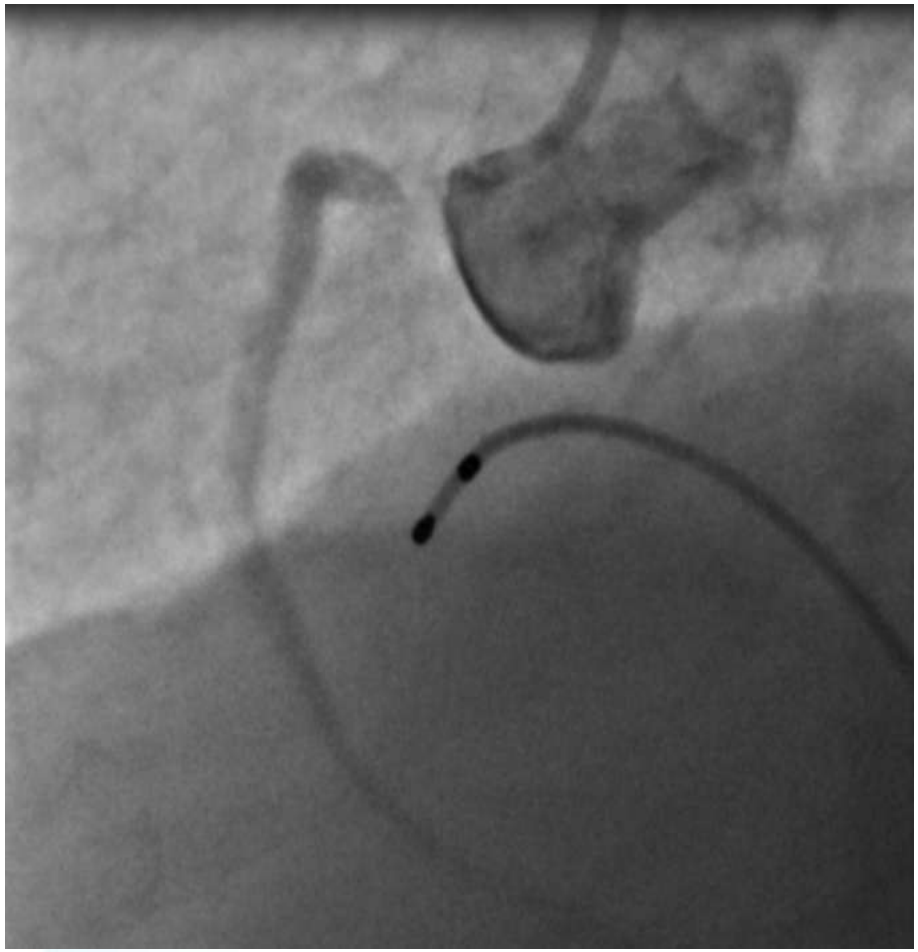

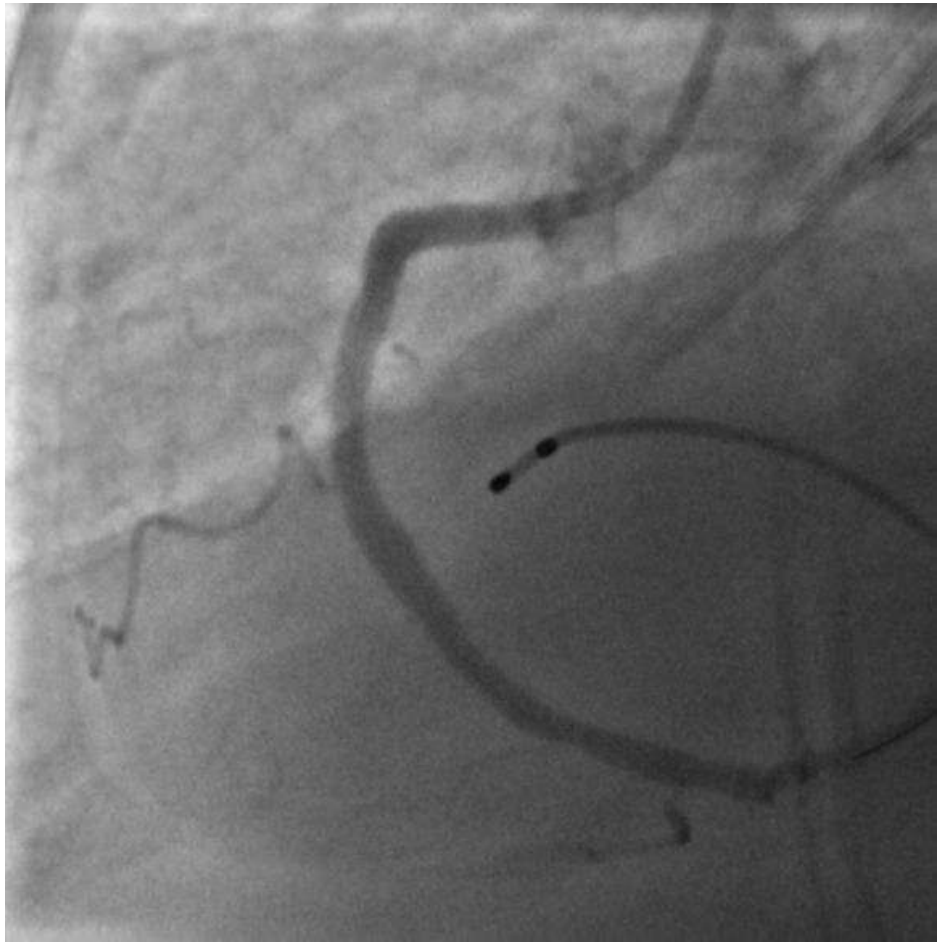

Have You Ever Experienced "Stent Regret?"

Post Stent Result:
single 2.75mm stent

Post Dilitation:
3.5x9mm non-compliant balloon for 30 seconds @ 22atm followed by 4.0x9mm non-compliant balloon for 30 seconds @ 16atm

Post Dilitation Result

SEVERE STENT UNDEREXPANSION

✓**This situation should be prevented by avoiding stent implantation unless adequate stenosis preparation has been performed with either balloon (inflated without waisting) or rotational atherectomy.**

✓**When aggressive post-dilatation has been attempted unsuccessfully, rotational atherectomy of under expanded stent *(STENT ABLATION)* has been reported as a viable option**

✓**In this case it might be advisable to proceed step by step by increasing burr size and by careful, slow advancement of the burr across the stent, in order to avoid burr entrapment**

Complications specifically seen with Rotational Atherectomy

- ✓Slow/no reflow
- ✓Distal embolization
- ✓Coronary spasm
- ✓Coronary perforation
- ✓Coronary dissection.

✓***Burr entrapment*** is one of rare but serious complications of the Rotablator, and previous report indicated that it occurred in 6 of 1,403 procedures (0.4%)

Stuck rotablator: the nightmare of rotational atherectomy

One rare but life-threatening complications is a stuck rotablator, also known as entrapment of α rotablation burr or trapped rotablator.

- The event can be defined as entrapment of the rotablation burr in a coronary lesion with the impossibility to rotate or retrieve the burr.
- Stuck rotablator can lead to acute coronary occlusion and sometimes requires immediate cardiac surgery

Burr entrapment occurs rarely with a reported incidence of 0.4%. (6 of 1,403 procedures)

Two mechanisms have been proposed previously.

1. **A small burr can be advanced beyond a heavily calcified plaque before sufficient ablation, especially when the burr is pushed firmly at high rotational speed.** During high speed rotation, the frictional heat may enlarge the space between plaques. Meanwhile, the coefficient of friction during motion is less than that at rest, which may facilitate the burr to pass the calcified lesion easily without debulking a significant amount of calcified tissue.

- In this situation, the ledge of calcium proximal to the burr may prevent burr withdrawal. **This phenomenon was named "kokesi"** after the Japanese doll by Kaneda *et al*

2. The burr can be entrapped within a severely calcified long lesion, especially angulated and concomitant coronary spasm.
   - **When a large burr was pushing vigorously against such lesion without sufficient pecking motion, the rotational speed may decrease significantly and this type of entrapment may occur.**

Accidental entrapment in or distally to the lesion. What to do????

1. Run away?
2. *Pray hard?*
3. Surgical advise?
4. Pull forcefully?

5. Use strong spasmolytics and try to pull?
6. Use a parallel wire and dilate with a ballon and then try to pull?
7. Other options ?

The simplest method to retrieve the entrapped burr is pulling back the rotablator system manually.

In some cases the stuck burr can be withdrawal successfully by manual traction with on-Dynaglide or off-Dynaglide rotation

But…….

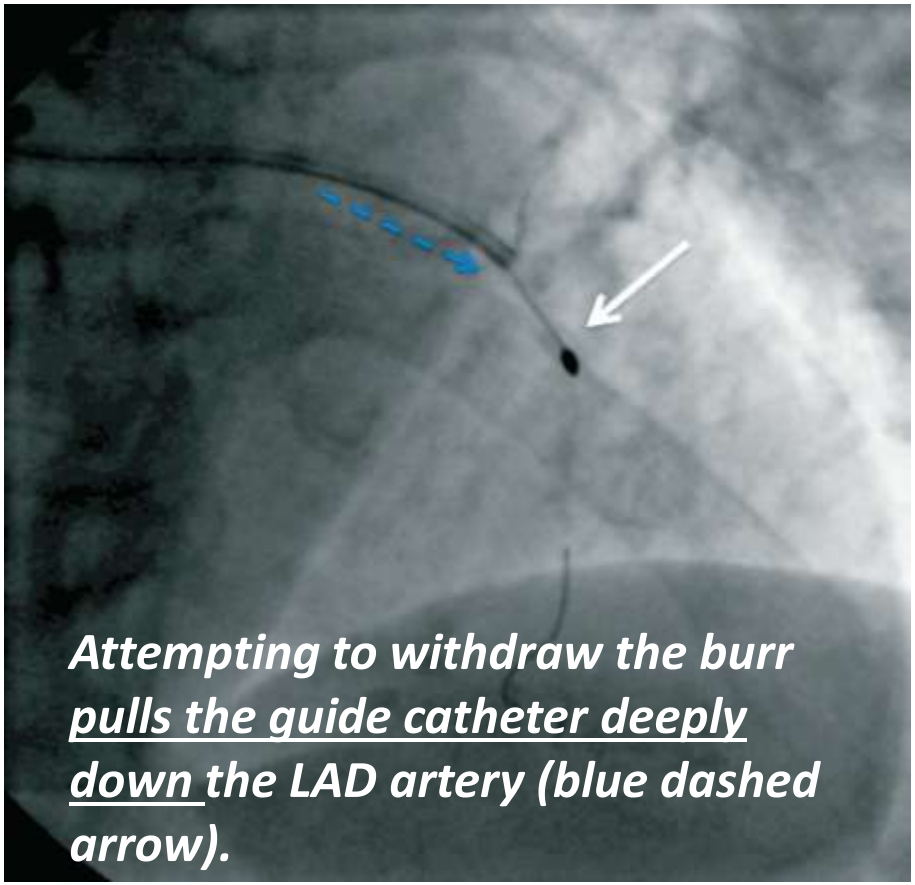

Attempting to withdraw the burr pulls the guide catheter deeply down the LAD artery (blue dashed arrow).

✓The vessel may perforate and proximal segment may be injured.

✓Extreme force on the burr and burr shaft may also result in shaft fracture.

Disengaged the GC from vessel ositum and sending another GW deep into aorta may prevent vessel injury by avoid deep seating of GC during traction.

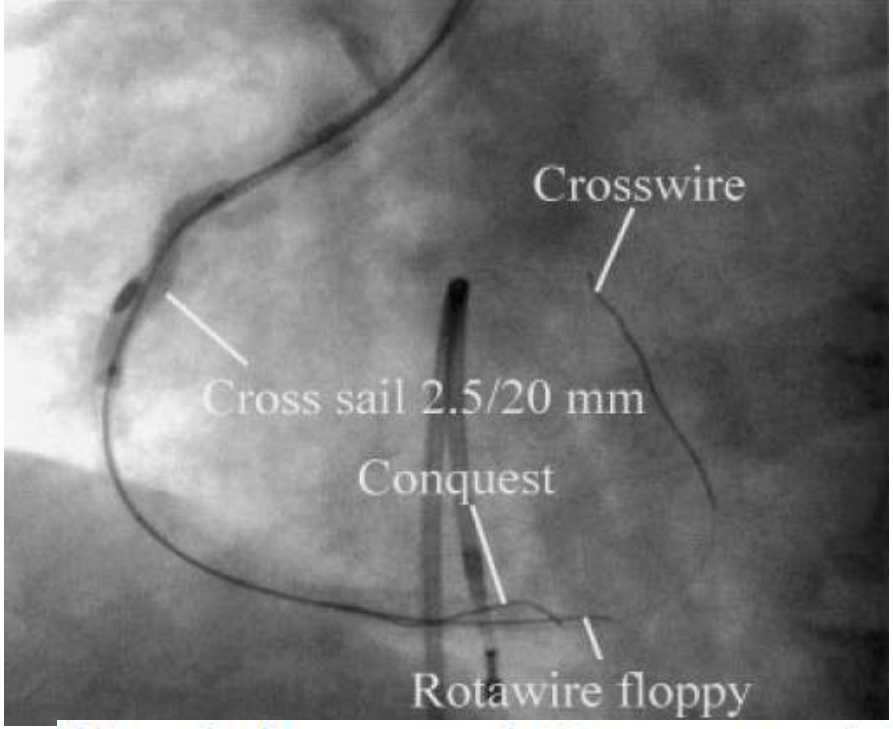

Recrossing another guide wire just beside the entrapped burr and making a crack between the burr and vessel wall by inflating a balloon catheter might be a more promising strategy

The lesion surrounding the entrapped burr is always heavily calcified and usually need a hydrophilic-coated wire to pass it and sometimes stiffer wire such as Conquest wire may be needed to pass the adjacent hard plaque

Usefulness of Conquest Guidewire for Retrieval of an Entrapped Rotablator Burr

Masayuki Hyogo,* MD, Naoto Inoue, MD, FSCAI, Reo Nakamura, MD, Takaomi Tokura, MD, Akiko Matsuo, MD, Keiji Inoue, MD, Tetsuya Tanaka, MD, PhD, and Hiroshi Fujita, MD, PhD

We experienced an entrapped rotablator burr that could not be retrieved even by deep seating of the guiding catheter. We successfully retrieved the burr by balloon inflation after the tapered tip of a Conquest wire managed to penetrate the quite hard plaque and pass through the outer lumen of the burr. *Catheter Cardiovasc Interv 2004;63:469–472.*

Disassembly of a Rotablator: Getting Out of a Trap

Ananth M. Prasan, MBBS, PhD, Manish Patel, MBBS, Mark R. Pitney, MBBS, and Nigel S. Jepson,* MBBS

The rotablator burr rarely becomes trapped within calcified lesions. Manual traction can be ineffective and dangerous. We report a case that illustrates a novel technique involving use of a percutaneous snare in conjunction with partial disassembly of the rotablator device to remove a trapped burr without need for open surgical intervention. *Cathet Cardiovasc Intervent 2003;59:463–465.*

Another approach, which requires a 7 Fr guide catheter, is to cut the proximal end of the atherectomy catheter shaft and RotaWire and advance a snare over the shaft down close to the lesion (Simultaneous traction on the snare and guiding catheter)

✓**This method, inspired by pacemaker lead extraction techniques**

✓**The use of a percutaneous snare in conjunction with partial disassembly of the rotablator apparatus allows the application of traction locally to the site of the entrapped burr in a more controlled fashion. This reduces the risk of traumatizing either the left main stem or other parts of the vasculature.**

Successful Retrieval of an Entrapped Rotablator Burr Using 5 Fr Guiding Catheter

Catheterization and Cardiovascular Interventions 78:558–564 (2011)

Masayoshi Kimura,* MD, Jun Shiraishi, MD, and Yoshio Kohno, MD

the LCx and in the LMT without difficulty. Conclusions: The 5 Fr straight guiding catheter might be useful for retrieving an entrapped burr (1.25-mm burr).

Alternatively, *after the shaft has been cut*, a child catheter (Heartrail® ST01; Terumo, Tokyo, Japan or GuideLiner®; Vascular Solutions, Minneapolis, MN, USA) can be advanced up to the burr: simultaneous traction on the burr shaft and counter-traction on the child catheter can result in successful retrieval of the trapped burr

GuideLiner, A Child-In-A-Mother Catheter for Successful Retrieval of an Entrapped Rotablator Burr

Catheterization and Cardiovascular Interventions 79:271–273 (2012)

Michael Cunnington, BMEDSCI, MBBS MRCP, MD, and
Mohaned Egred,* BSC(HONS), MB, CHB, FRCP, MD

can be attempted. We describe a novel technique to remove a trapped rotablator burr from a heavily calcified lesion using counter-traction with a GuideLiner, child-in-a-mother catheter, which successfully removed the entrapped burr without the need for surgery when simple traction alone had been ineffective.

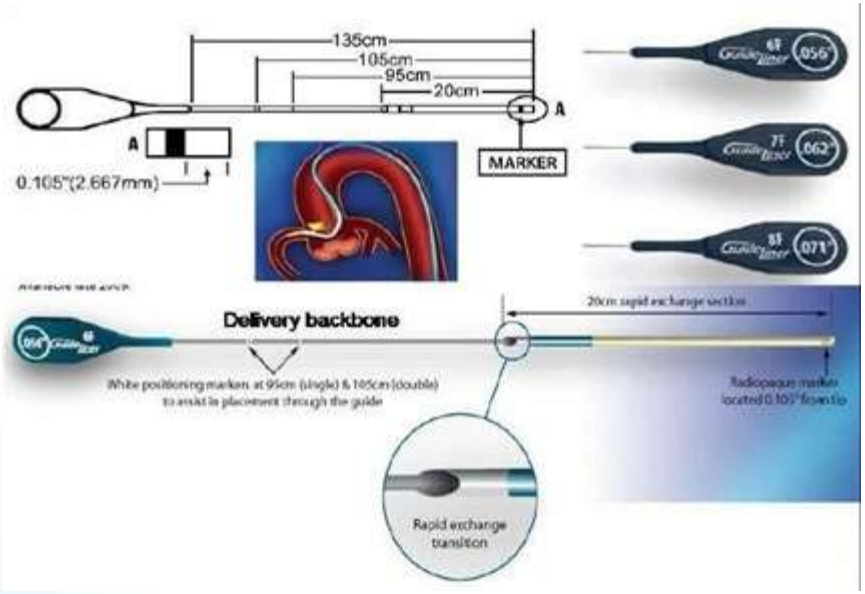

There are a number of manoeuvers which can be tried, but if all are unsuccessful, then the patient will require emergency surgery.

Trapped Rotablator: Kokesi Phenomenon

Hideaki Kaneda,* MD, Shigeru Saito, MD, George Hosokawa, MD, Shinji Tanaka, MD, and Yoshitaka Hiroe, MD

We experienced a rare complication of rotational atherectomy. The burr was trapped at the angled, calcified narrowing in the left anterior descending coronary artery. The burr was retrieved after the resection of the pulmonary artery and the left coronary artery. We will discuss the cause and prevention of this complication. *Cathet. Cardiovasc. Intervent. 49:82–84, 2000.*

How to prevent burr entrapment?

✓Gentle pecking motion and short runs of rotablation (< 15 s)

✓operators should start RA in eccentric and extremely calcified lesions <u>with relatively small burrs and a higher speed of rotation.</u>

✓ When a smaller burr was employed, <u>more slowly advancement to ablate the plaque of proximal lesion sufficiently was recommended</u>, and too high a burr speed should also be avoided to prevent "kokesi phenomenon

✓Operators should not exert <u>excessive forward force during burr advancement</u> and <u>should avoid significant decelerations of rotational speed (>5000 rpm)</u> in order to avoid entrapment.

Choice, not circumstances, determines your *success*

DES implantation after rotational atherectomy demostrated significant reduction in TLR

Author/y	Patient Number (N)	Age (y)	In-hospital deaths/MACE (N) (%)	Mean FU	FU MACE/TLR/TVR (%)
Clavijo LC et al 2006	81	71.5 ± 9.6	0 (0%)/1 (1.3%)	6 mo	11.0/4.2/??
Furuichi S et al 2009	95	68 ± 9	0 (0%)/3 (3.2%)	17.4 mo	15.8/9.5/11.6
Tamekiyo H et al 2009	79	70.6 ± 10.7	2 (2.5%)/3 (3.8%)	730 d	30.1/25.0/??
García de Lara et al 2010	50	70 ± 1.2	2 (4%)/2 (4%)	14 mo	8.0/6.0/??
Rathore et al 2010	391	70.8 ± 8.8	4 (1%)/10 (2.5%)	6–9 mo	?/10.6/?
Mezilis N et al 2010	150	70 ± 8	0 (0%)/0 (0%)	3 y	11.3/2.0/2.0
Benezet J et al 2011	102	68.8 ± 7.4	1 (0.9%)/3 (2.9%)	15 mo	12.7/8.8/?
Chiang MH et al 2011[e]	67	73.2 ± 10.3	5 (7.5%)/5 (7.5%)[f]	23 mo	17.9/10.4/10.4

Rotablator: bifurcation lesions

Mechanical debulking prior to stenting of bifurcation lesions has been proposed to prevent plaque shifting in order to acieve side branch patency

Debulking followed by adjunctive post-dilatation was associated with a:
- ✓ **Significant improvement in procedural success (97% vs 73%, p<0.01),**
- ✓ **Larger post-procedural diameters and**
- ✓ **reduction in TVR in 1-year follow-up**

Although not routinely applied in bifurcation lesions, rotational atherectomy of the main branch before stent implantation *might be an option to enable simple-stenting strategy even in the presence of eccentric, calcified plaque* which might jeopardise the side branch

In bifurcation lesions the mainstay of treatment is branch preservation and adequate lumen in both limbs. Rotablation should be started at the most difficult to wire branch first. Use low burr-artery ratios (<0.5) especially when there is angulation present.

Stentablation as a Successful Treatment Strategy for Stent Underdeployment due to Calcified Plaque

J Clinic Experiment Cardiol 2012, 3:4

Chelliah RK*, Bourantas C, Thackray SD and Alamgir MF

Hull & East Yorkshire Centre for Cardiology & Cardiothoracic Surgery, Castle Hill Hospital, Cottingham HU16 5JQ, UK

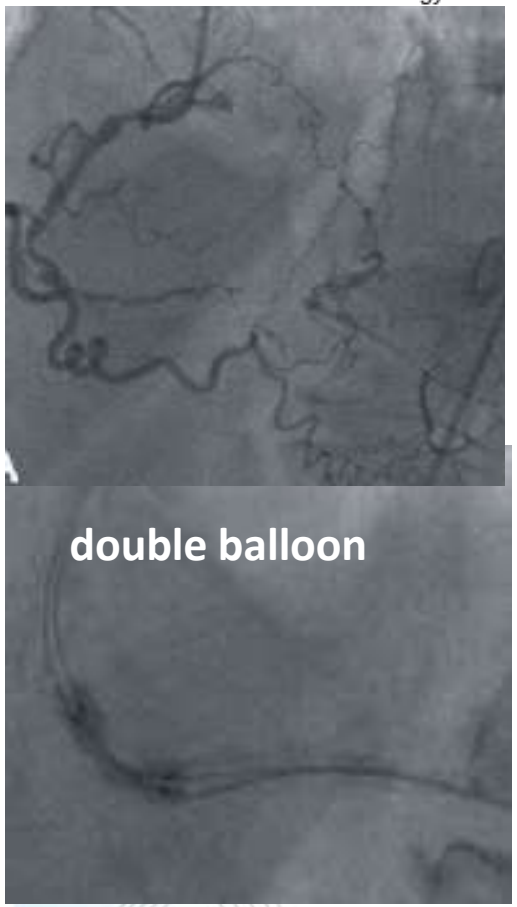

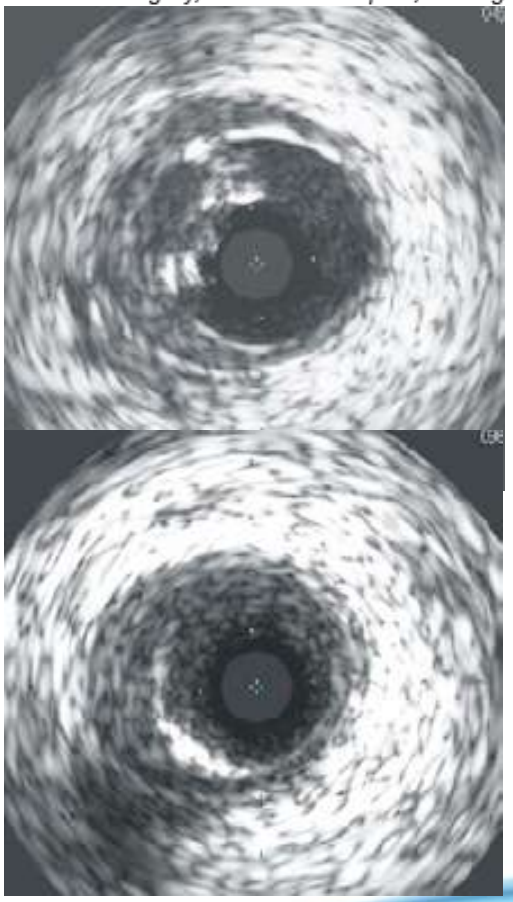

Rota-Rescue

Inability to deliver a stent

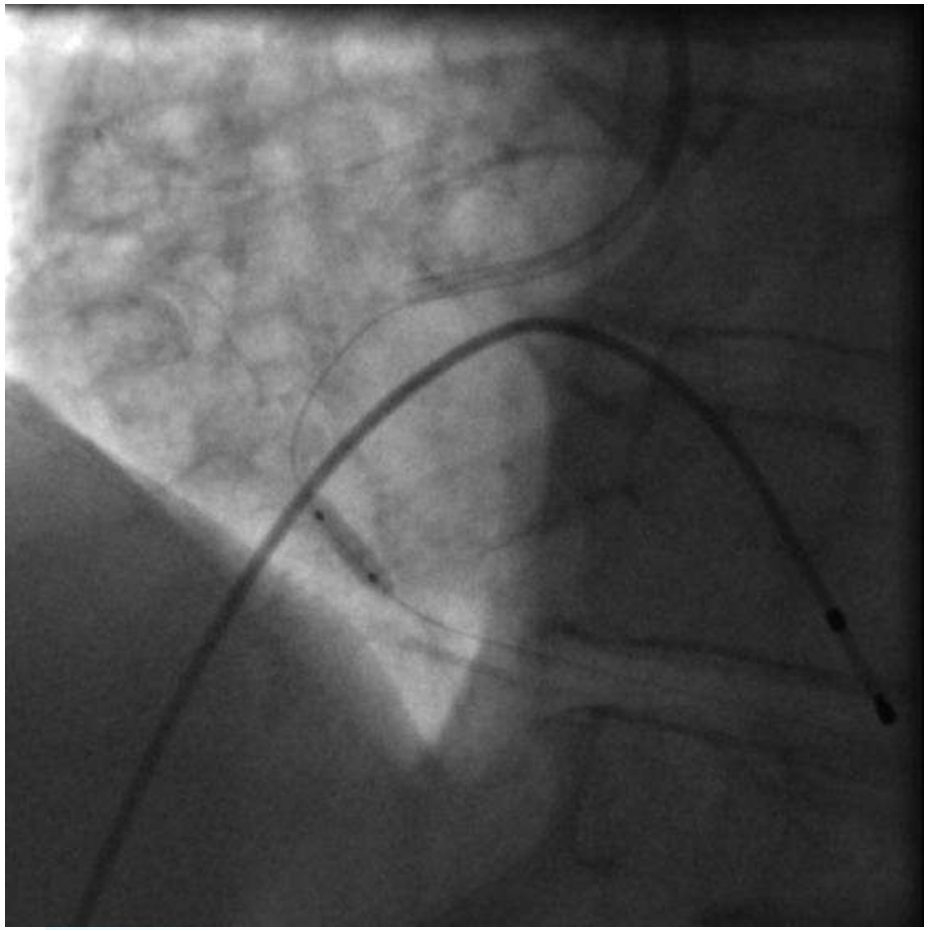

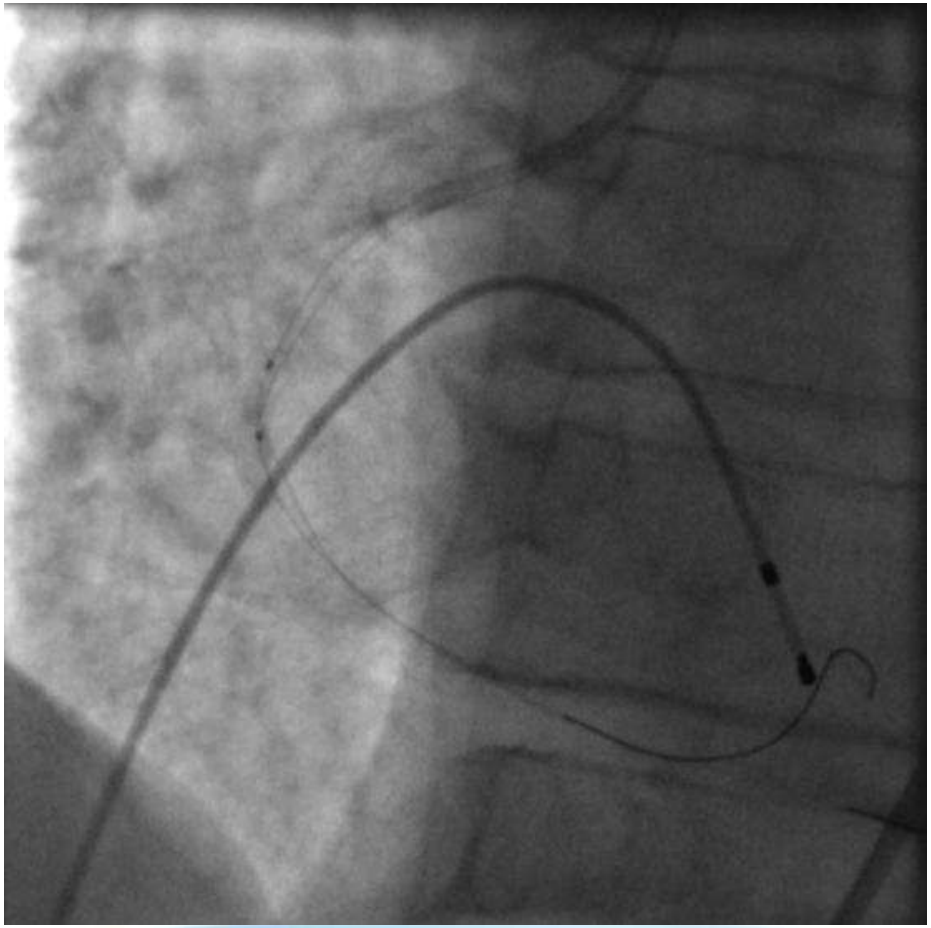

Rotablator :ostial lesions

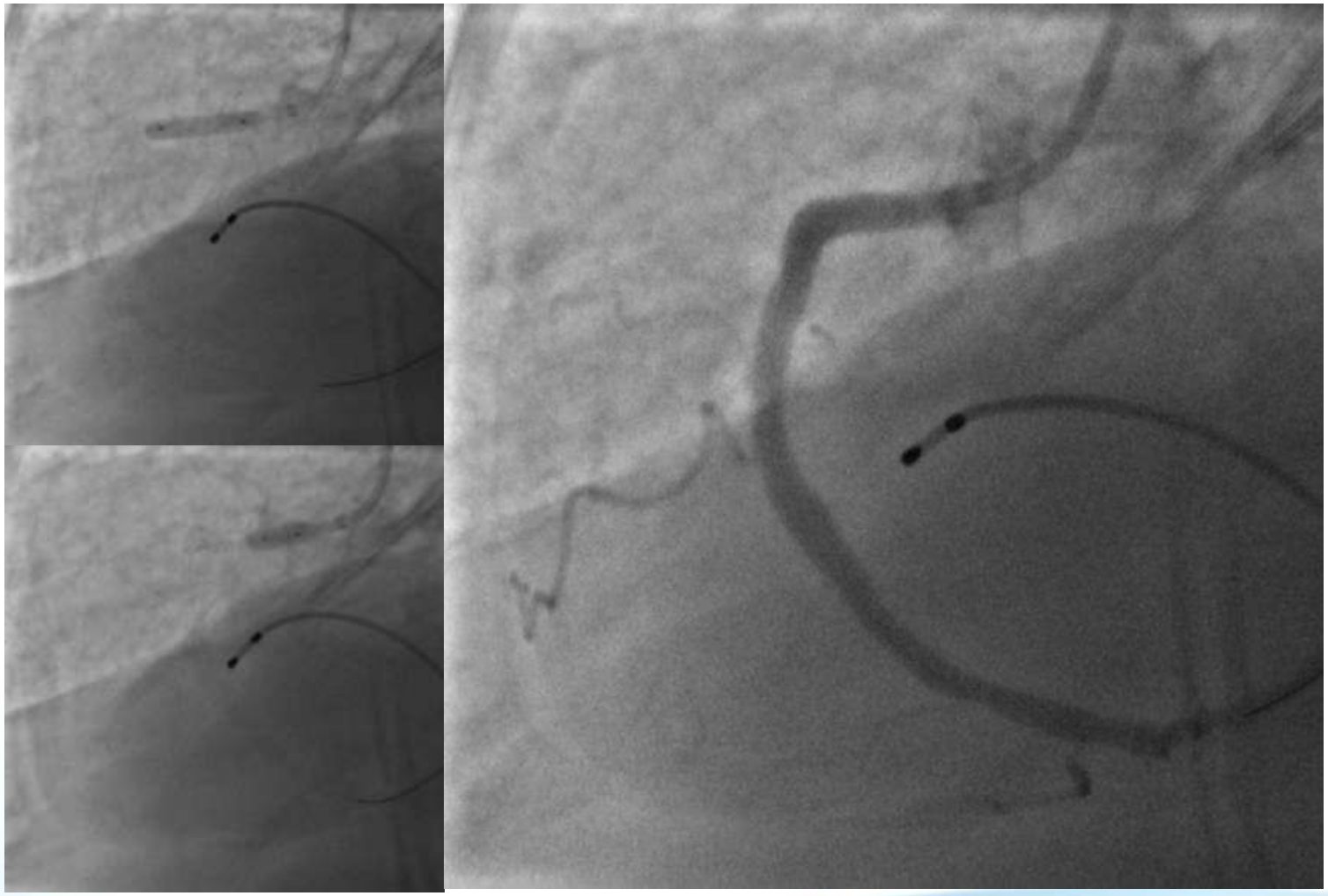

Rota-Rescue
Non Dilatable lesions

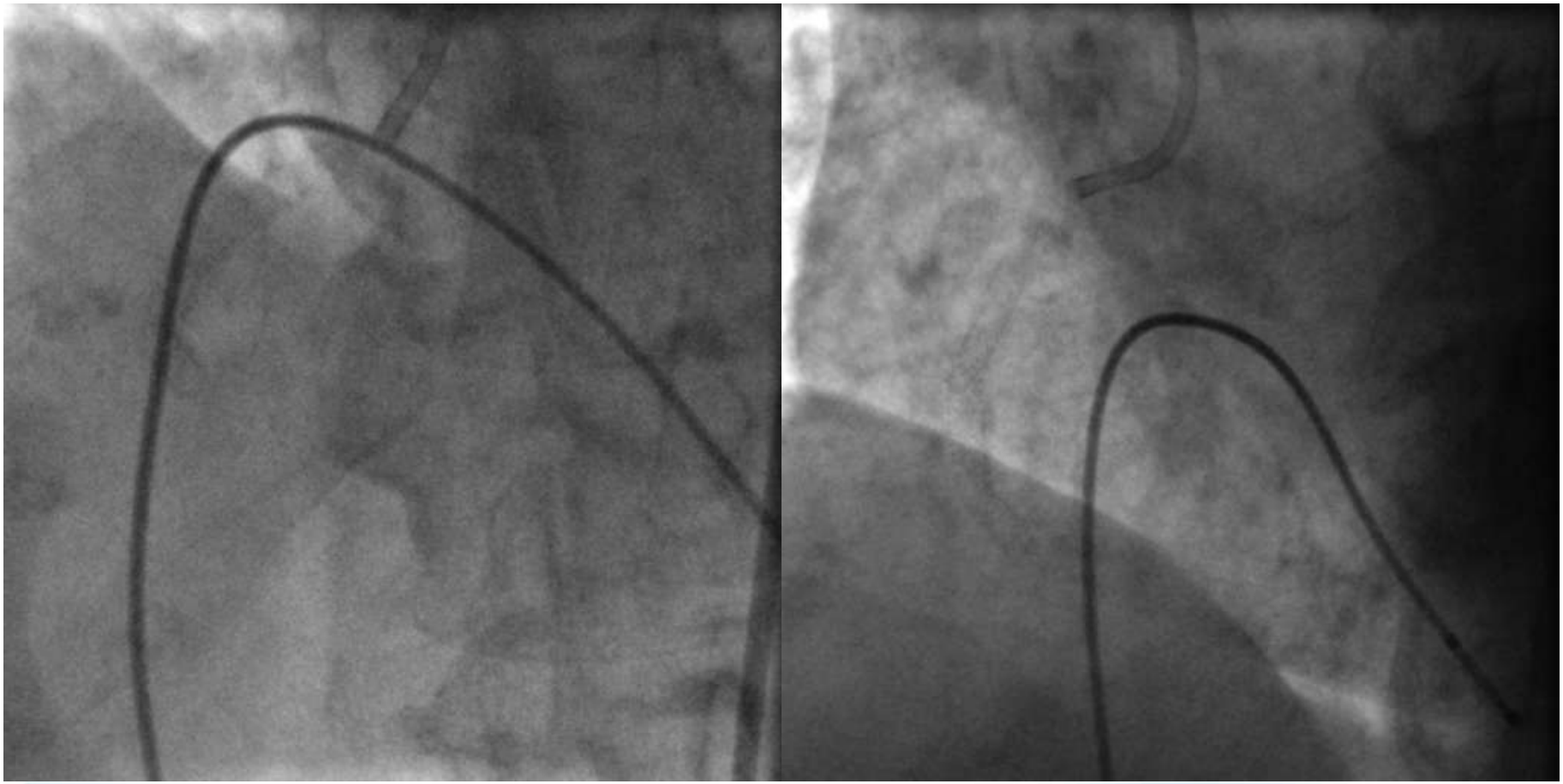

Rota-Rescue
Non Dilatable lesions

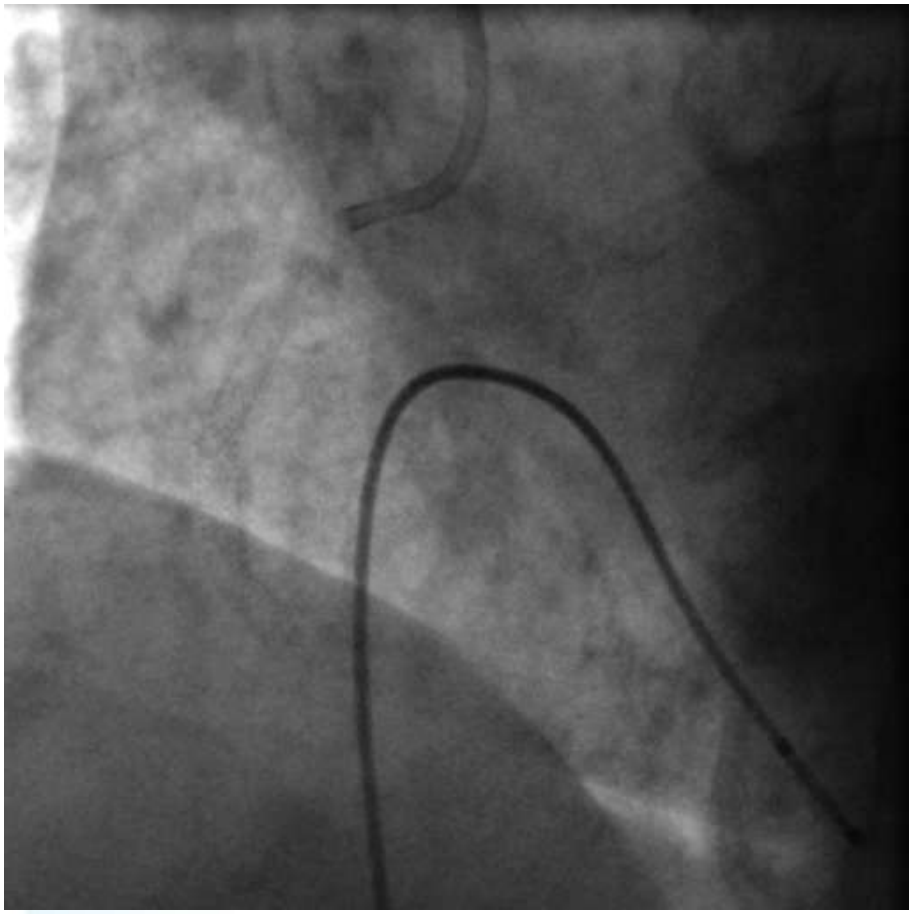

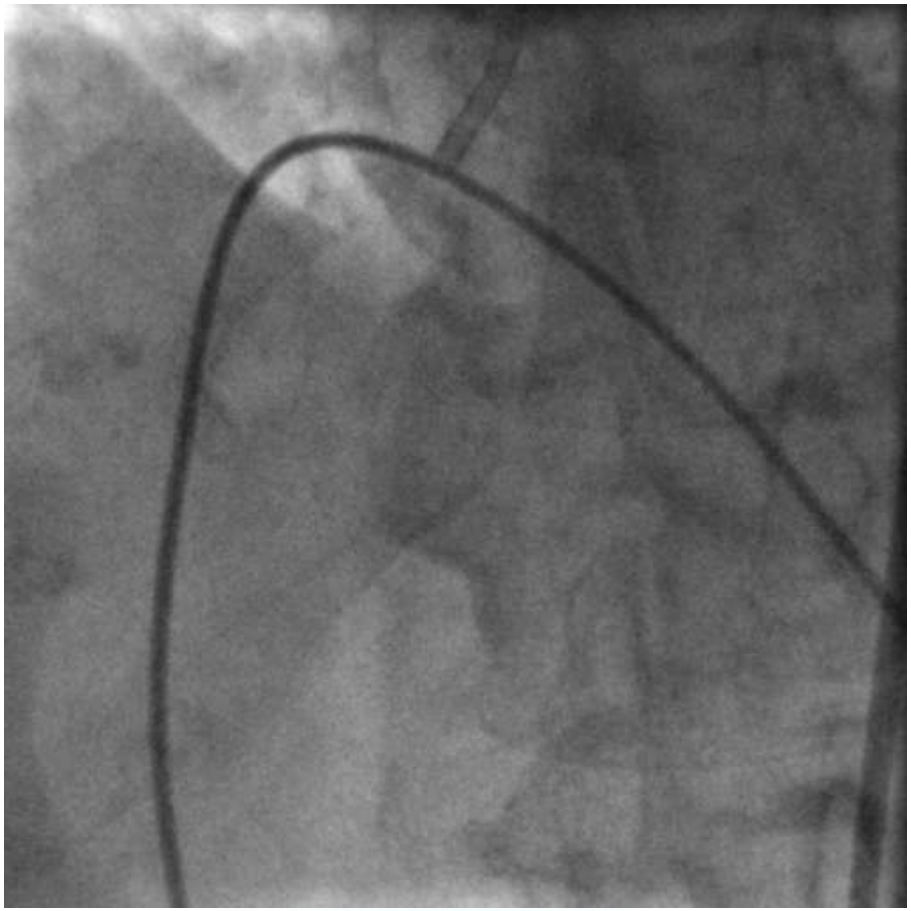

Clin Med Insights Cardiol. 2012;6:53-6. doi: 10.4137/CMC.S8959. Epub 2012 Feb 20.

A different way of coronary lesion preparation: stentablation and rotastenting.

Akin I, Pohlmann S, Nienaber CA, Ince H.

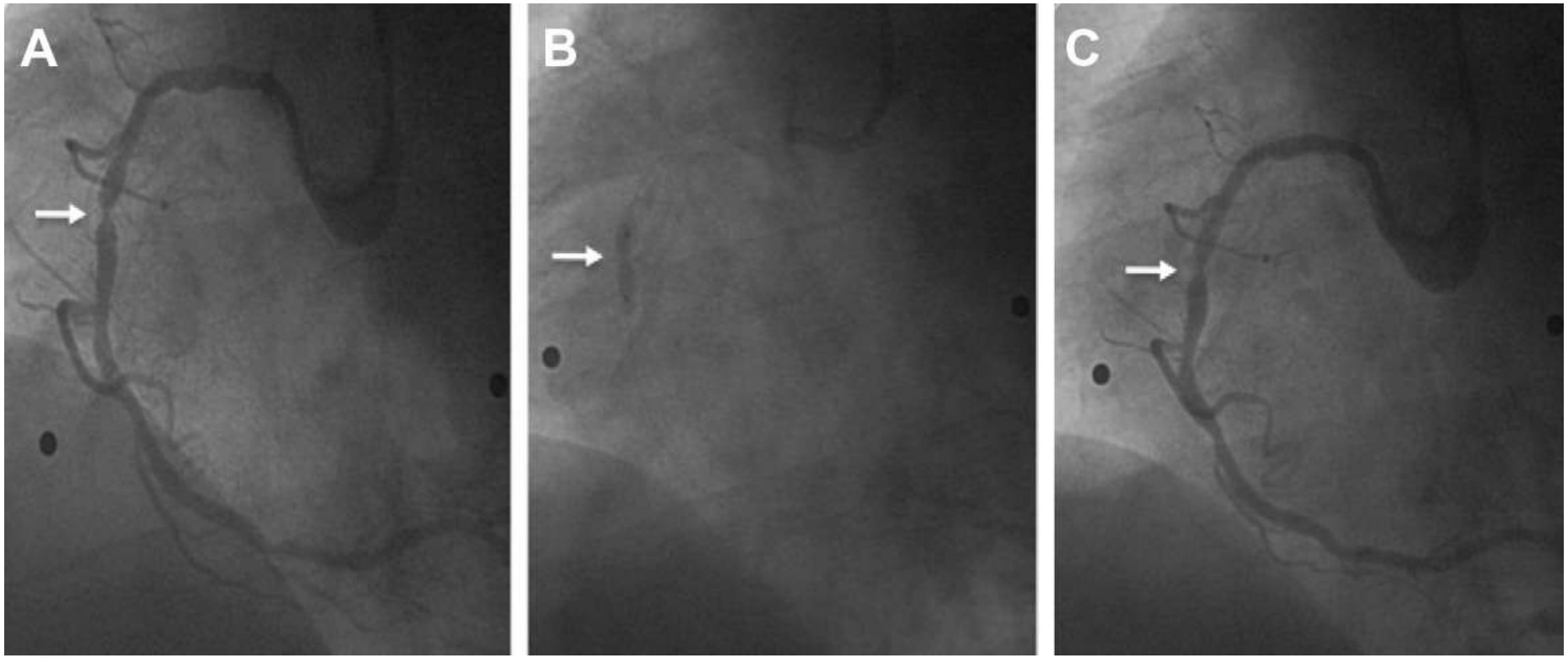

Coronary angiography reveals a 90% stenosis of the right coronary artery (RCA) (A). Direct stenting of the bare metal stent (BMS) results in an underexpansion (B) and residual stenosis in the mid-part (C).

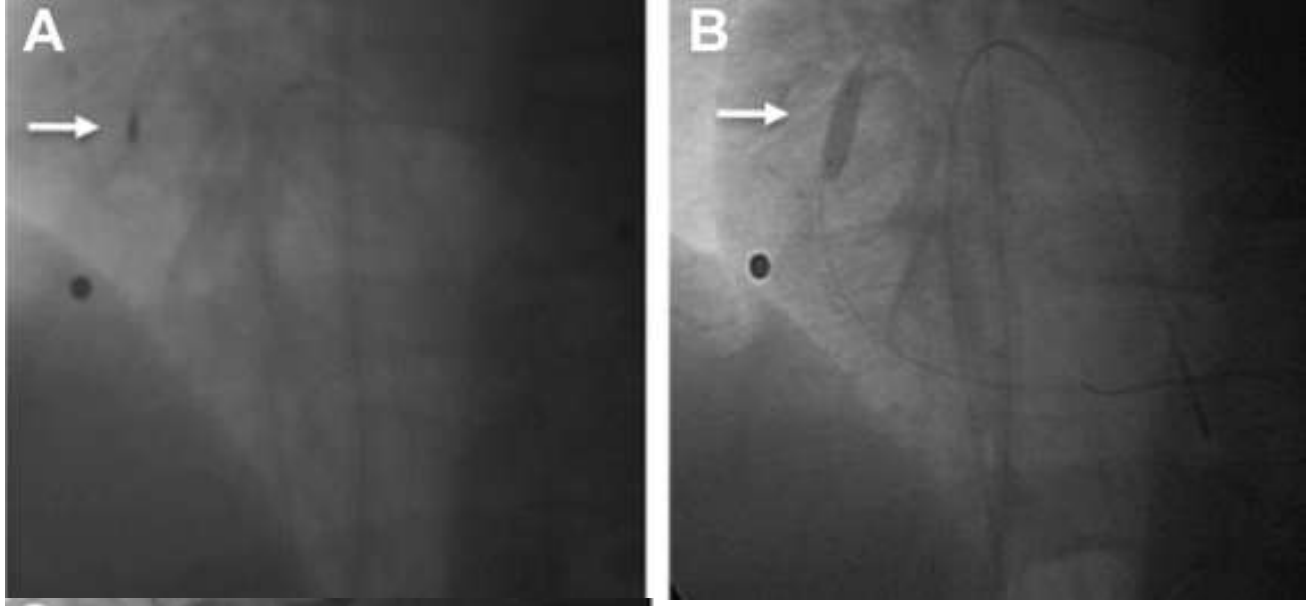

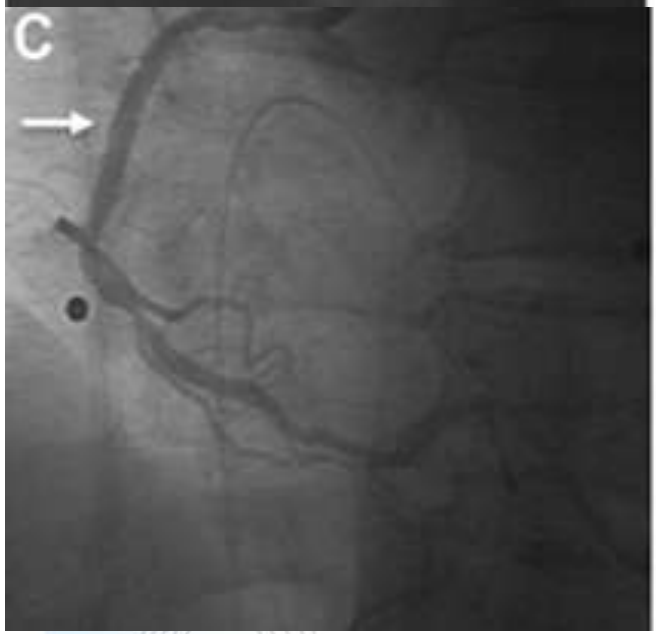

Rotational atherectomy of the remaining calcified stenosis within the stent and the underexpanded stent struts (stentablation) (A) with acceptable result in the following angiography. Drug eluting stent (DES) implantation (rotastenting) (B) after rotational atheterctomy without any evidence for residual stenosis in final angiogram (C)

There is no space to advance guidewires or balloons through the 6F guide catheter



Dual Catheter Technique

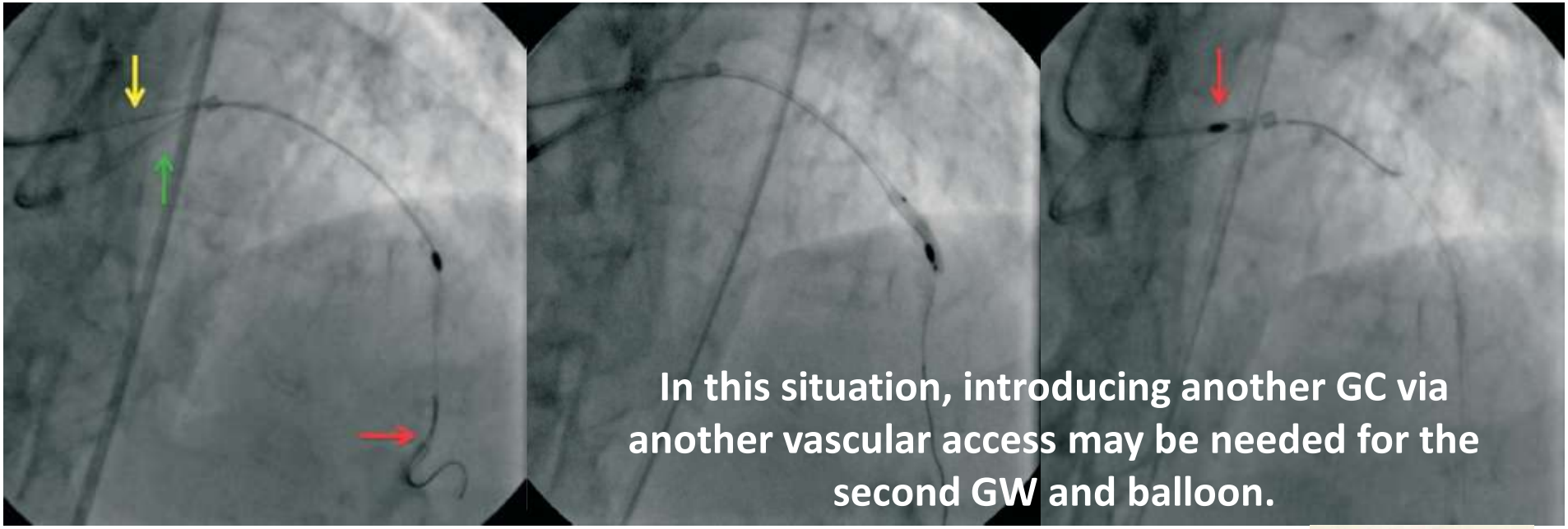

The profile of the rotablation drive shaft sheath is 4.3 Fr, which may prohibit introducing of a balloon catheter (mostly 3 Fr in diameter) into the GC if it is a 6 or 7 Fr one.

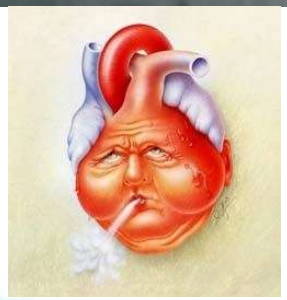

Rota-Rescue :Save the time and expense

Rotational atherectomy is one of the few techniques ***that can quickly and elegantly address the difficulty of traversing these heavily calcified arteries by metal stents***, no matter how tightly they are affixed to their balloon catheters or how compliant and flexible the delivery system is rendered by their manufacturers.